Anesthesiology 2007; 106:591–614 Copyright © 2007, the American Society of Anesthesiologists, Inc. Lippincott Williams & Wilkins, Inc.

Pathogenesis, Diagnosis, and Treatment of Lumbar Zygapophysial (Facet) Joint Pain

Steven P. Cohen, M.D., Srinivasa N. Raja, M.D.†*

CME This article has been selected for the *Anesthesiology* CME Program. After reading the article, go to http://www.asahq.org/journal-cme to take the test and apply for Category 1 credit. Complete instructions may be found in the CME section at the back of this issue.

Lumbar zygapophysial joint arthropathy is a challenging condition affecting up to 15% of patients with chronic low back pain. The onset of lumbar facet joint pain is usually insidious, with predisposing factors including spondylolisthesis, degenerative disc pathology, and old age. Despite previous reports of a "facet syndrome," the existing literature does not support the use of historic or physical examination findings to diagnose lumbar zygapophysial joint pain. The most accepted method for diagnosing pain arising from the lumbar facet joints is with low-volume intraarticular or medial branch blocks, both of which are associated with high false-positive rates. Standard treatment modalities for lumbar zygapophysial joint pain include intraarticular steroid injections and radiofrequency denervation of the medial branches innervating the joints, but the evidence supporting both of these is conflicting. In this article, the authors provide a comprehensive review of the anatomy, biomechanics, and function of the lumbar zygapophysial joints, along with a systematic analysis of the diagnosis and treatment of facet joint pain.

SINCE its original description almost 100 yr ago, thousands of scientific articles have been published on lumbar zygapophysial (l-z) joint pain, and facet interventions represent the second most common type of procedure performed in pain management centers throughout the United States.[1] But despite the plethora of research and clinical emphasis on this disorder, almost every aspect of l-z joint pain, from diagnosis to treatment, remains mired in controversy. Even among pain specialists, lumbar facet joint pain remains a misunderstood, misdiagnosed, and improperly treated medical condition. In this article, l-z joint pain is defined in a functional capacity as pain originating from any structure integral to both the function and configuration of the lumbar facet joints, including the fibrous capsule, synovial membrane, hyaline cartilage surfaces, and bony articulations.

A critical issue that must be addressed before embarking on any review of l-z joint pain is whether pain can be definitively attributed to these joints. In the 1960s and 1970s, this question posed a legitimate controversy that was vigorously debated in the medical literature.[2,3] However, in the past 20 yr, the scales of this controversy have resolutely tipped toward the conviction that l-z joints can be and often are a primary source of low back pain (LBP).[4]

Compelling evidence underlies this paradigmatic shift in thinking. The facet joint capsule and surrounding structures are richly imbued with nociceptors that fire when the capsule is stretched or subjected to local compressive forces.[5,6] In both pain patients and volunteers, chemical or mechanical stimulation of the facet joints and their nerve supply has been shown to elicit back and/or leg pain.[7–10] During spine surgery performed under local anesthetic (LA), lumbar facet capsule stimulation elicits significant pain in approximately 20% of patients.[11] Last and most significantly, LA blocks of either the facet joints themselves or the medial branches innervating them have been shown to relieve pain in a substantial percentage of patients with chronic LBP.[12] Therefore, like other synovial joints in the human body, the l-z joints represent a potential pain generator in patients with chronic LBP.

In light of the prevalence of lumbar facet joint pain and the frequency with which facet blocks are performed, several reviews have been undertaken on this phenomenon in the past 15 yr. Although some of these articles provided keen insight on various aspects of the condition, most were limited by their confined scope and specialized target audiences. The purpose of this review is therefore to provide a comprehensive, evidence-based framework on the anatomy, pathophysiology, prevalence, diagnosis, and treatment of lumbar facet pain. Articles reviewed were obtained *via* MEDLINE and Ovid search engines, books and book chapters, and bibliographic references dating to the early 1900s.

Historic Review

The l-z joints, often referred to as facet joints, have long been recognized as a potential source of LBP. In 1911, Goldthwaite[13] first noted that the peculiarities of

* Associate Professor, Department of Anesthesiology and Critical Care Medicine, Johns Hopkins School of Medicine, Baltimore, Maryland, and Walter Reed Army Medical Center, Washington, D.C. † Professor, Department of Anesthesiology and Critical Care Medicine and Department of Neurology, Johns Hopkins School of Medicine.

Received from the Pain Management Division, Department of Anesthesiology and Critical Care Medicine, Johns Hopkins School of Medicine, Baltimore, Maryland. Submitted for publication May 16, 2006. Accepted for publication October 24, 2006. The opinions or assertions contained herein are the private views of the authors and are not to be construed as official or as reflecting the views of the Department of the Army or the Department of Defense. Dr. Cohen receives partial salary support from the John P. Murtha Neuroscience and Pain Institute, Johnstown, Pennsylvania, and the US Army. Dr. Raja has unrestricted grants from Allergan (Irvine, California) and Ortho-McNeil (Raritan, New Jersey), and serves as scientific advisor for Fralex Therapeutics (Toronto, Ontario, Canada). He receives salary support from grant No. NS-26363 from the National Institutes of Health, Bethesda, Maryland.

Address correspondence to Dr. Cohen: Division of Pain Medicine, Johns Hopkins School of Medicine, 550 North Broadway, Suite 301, Baltimore, Maryland 21205. scohen40@jhmi.edu. Individual article reprints may be accessed at no charge through the Journal Web site, www.anesthesiology.org.

Copyright © by the American Society of Anesthesiologists. Unauthorized reproduction of this article is prohibited.

Downloaded from http://pubs.asahq.org/anesthesiology/article-pdf/106/3/591/363690/0000542-200703000-00024.pdf by guest on 23 September 2024

the facet joints could be a significant source of back pain and instability. Sixteen years later, after anatomical dissections of 75 cadavers, Putti[14] suggested that local inflammation and degenerative changes in lumbar facet joints could result in sciatica from irritation of nerve roots. In 1933, Ghormley[15] coined the term "facet syndrome," which he defined as lumbosacral pain, with or without sciatica, that was likely to occur after a sudden rotatory strain. Shortly thereafter, interest in the l-z joints as potential sources of back pain waned after the landmark article by Mixter and Barr[16] implicating lumbar disc rupture as the major cause of low back and leg pain. The 1940s saw a resurgence in the interest of l-z joints as pain generators when Badgley[17] suggested that up to 80% of cases of LBP and sciatica are due to referred pain from l-z joint pathology, rather than direct nerve root compression. In 1963, Hirsch *et al.*[7] published the first account whereby the injection of l-z joints reproduced patients' back pain. Rees,[18] who reported a success rate of 99.8%, is generally credited with promoting percutaneous "facet rhizolysis" with his ground-breaking report in the early 1970s. Later, it was shown that the technique advocated by Rees may not have been sufficient to achieve rhizotomy in most patients.[3] Buoyed by a high incidence of hemorrhagic complications, Shealy[19,20] pioneered the use of fluoroscopically guided radiofrequency facet denervation to treat l-z joint pain in the mid-1970s.

Anatomy and Innervation

The lumbar facet joints form the posterolateral articulations connecting the vertebral arch of one vertebra to the arch of the adjacent vertebra. As true synovial joints, each facet joint contains a distinct joint space capable of accommodating between 1 and 1.5 ml of fluid, a synovial membrane, hyaline cartilage surfaces, and a fibrous capsule.[21] The fibrous capsule of the lumbar facet joint is approximately 1 mm thick and composed mostly of collagenous tissue arranged in a more or less transverse fashion to provide maximum resistance to flexion.[22,23] The joint capsule is thick posteriorly, supported by fibers arising from the multifidus muscle. Superiorly and inferiorly, the capsule attaches further away from the osteochondral margins, forming subcapsular recesses that in the normal joint are filled with fibroadipose menisci. Anteriorly, the fibrous capsule is replaced by the ligamentum flavum.[24]

Each facet joint receives dual innervation from medial branches arising from posterior primary rami at the same level and one level above the z-joint.[25,26] For example, the inferior pole of the L4–L5 facet joint receives innervation from the L4 medial branch and its superior pole is innervated by the L3 medial branch, which are typically blocked on the transverse processes of L5 and L4, respectively. The medial branches of L1–L4 dorsal rami course across the top of their respective transverse processes one level below the named spinal nerve (*e.g.*, L4 crosses the transverse process of L5), traversing the dorsal leaf of the intertransverse ligament at the base of the transverse process. Each nerve then runs downward along the junction of the transverse and superior articular processes, passing beneath the mamilloaccessory ligament and dividing into multiple branches as it crosses the vertebral lamina (fig. 1). In some cases, the mamilloaccessory ligament becomes calcified, which may lead to nerve entrapment.[27] This is most common at L5 (approximately 20%) but also occurs at L4 (10%) and L3 (4%). In addition to two l-z joints, the medial branches also innervate the multifidus muscle, the interspinous muscle and ligament, and the periosteum of the neural arch.[7,28–30] The L5 nerve differs in that it is the dorsal ramus itself that runs along the junction of the sacral ala and superior articular process of the sacrum.[29,31] Its medial branch arises opposite the inferolateral corner of the base of the lowest facet joint. At this level, it is the dorsal ramus rather than its medial branch that is amenable to blockade.

Some people may have aberrant or additional innervation of the facet joints. In a study conducted in asymptomatic volunteers, Kaplan *et al.*[32] found that 1 in 9 subjects who underwent L4–L5 (n = 5) and L5–S1 (n = 4) facet joint medial branch blocks (MBB) felt pain dur-

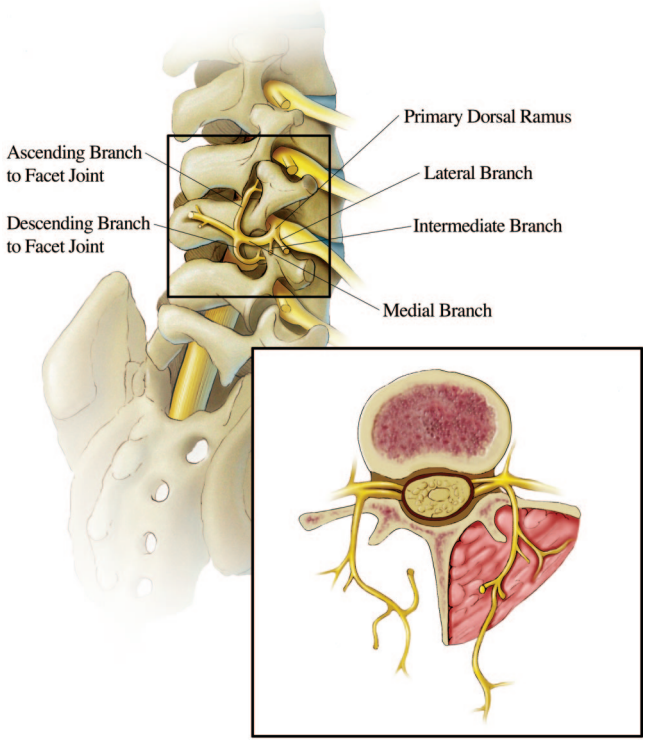

Fig. 1. Right lateral oblique view of the lumbar vertebral bodies and the dorsal rami medial branches. Drawing by Frank M. Cort, M.S. (Research Associate, Department of Radiology, Johns Hopkins Hospital, Baltimore, Maryland).

Copyright © by the American Society of Anesthesiologists. Unauthorized reproduction of this article is prohibited.
Downloaded from http://pubs.asahq.org/anesthesiology/article-pdf/106/3/591/363690/0000542-200703000-00024.pdf by guest on 23 September 2024

ing repeated capsular distension concordant with pain experienced during previous l-z joint provocation without MBB. Assuming the blocks were technically successful, one explanation for this finding is that in a small subset of individuals, aberrant innervation may account for false-negative diagnostic MBB. Some authors have suggested that l-z joints may also receive innervation from the medial branch below the joint (*i.e.*, S1 for the L5–S1 joint),[33,34] the dorsal root ganglion,[35] and the paravertebral sympathetic ganglia,[36,37] but these assertions remain unproven (fig. 2).

Histologic studies have demonstrated that the lumbar facet joints are richly innervated with encapsulated (Ruffini-type endings, pacinian corpuscles), unencapsulated, and free nerve endings.[5] The presence of low-threshold, rapidly adapting mechanosensitive neurons suggests that in addition to transmitting nociceptive information, the l-z facet capsule also serves a proprioceptive function. Besides substance P and calcitonin gene–related peptide, a substantial percentage of nerve endings in facet capsules have also been found containing neuropeptide Y, indicating the presence of sympathetic efferent fibers.[38,39] Nerve fibers have also been found in subchondral bone and intra-articular inclusions of l-z joints, signifying that facet-mediated pain may originate in structures besides the joint capsule.[40–42] In degenerative lumbar spinal disorders, inflammatory mediators such as prostaglandins[43] and the inflammatory cytokines interleukin 1β, interleukin 6, and tumor necrosis factor α[44] have been found in facet joint cartilage and synovial tissue.

Function and Biomechanics

The basic anatomical unit of the spine, often referred to as the three-joint complex, consists of the paired zygapophysial joints and the intervertebral disc. Together, these joints function to support and stabilize the spine, and prevent injury by limiting motion in all planes of movement. Macroscopically, each facet joint is composed of a posteromedially facing concave superior articular process from the inferior vertebral body, and a smaller anterolaterally facing inferior articular process from the superior spinal level. The shape and orientation of the l-z joints determine the role each plays in protecting the spine against excessive motion. Facet joints oriented parallel to the sagittal plane provide substantial resistance to axial rotation but minimal resistance to shearing forces (backward and forward sliding), whereas joints oriented more in a coronal plane tend to protect against flexion and shearing forces but provide minimal protection against rotation (fig. 3).[24] In an anatomical study published in 1940 by Horwitz and Smith,[45] the authors found that the L4–L5 z-joints tended to be more coronally positioned (almost 70° with respect to the sagittal plane), whereas the L2–L3 and L3–L4 joints were likely to be oriented more parallel (< 40°) to the sagittal plane. In more recent studies by Masharawi *et al.*[46] and Punjabi *et al.*,[47] the investigators found that the upper lumbar facet joints (T12–L2) were oriented closer to the midsagittal plane of the vertebral body (mean range, 26°–34°), whereas the lower facet joints tended to be oriented away from that plane (40°–56°). In the upper lumbar spine, approximately 80% of the facet joints are curved, and 20% are flat. In the lower lumbar spine, these numbers are reversed.[45] Studies by Grobler *et al.*[48] and Boden *et al.*[49] found a positive association between degenerative spondylolisthesis and more sagittally oriented lower lumbar facet joints.

In young people, the l-z joints are quite strong, capable

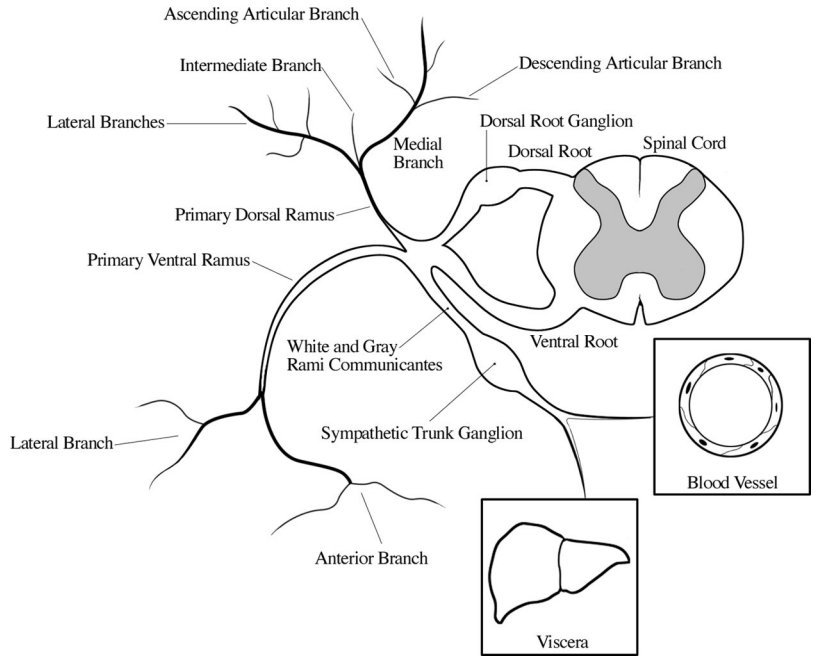

Fig. 2. Schematic drawing of the spinal cord and segmental spinal innervation. Drawing by Specialist Frank and Angela Dill, US Army, and Frank M. Cort, M.S. (Research Associate, Department of Radiology, Johns Hopkins Hospital, Baltimore, Maryland).

Copyright © by the American Society of Anesthesiologists. Unauthorized reproduction of this article is prohibited.
Downloaded from http://pubs.asahq.org/anesthesiology/article-pdf/106/3/591/363690/0000542-200703000-00024.pdf by guest on 23 September 2024

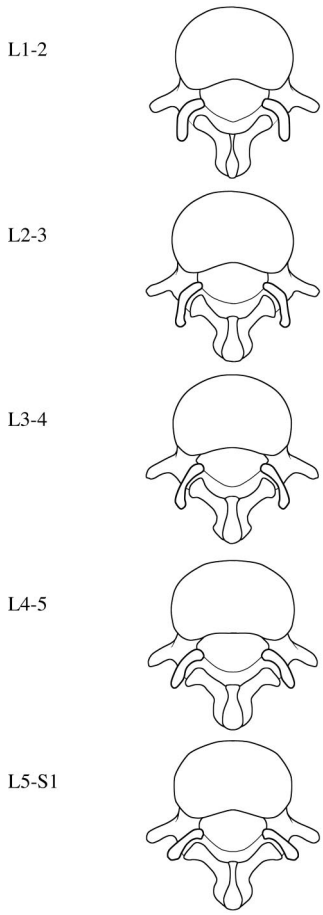

Fig. 3. Segmental variation in lumbar zygapophysial facet joint orientation in the transverse plane. Adapted from Taylor and Twomey[277] and Masharawi *et al.*[46] Drawings by Specialist Frank and Angela Dill, US Army, and Frank M. Cort, M.S. (Research Associate, Department of Radiology, Johns Hopkins Hospital, Baltimore, Maryland).

of supporting almost twice body weight.[23] As aging occurs, the joints become weaker and more biplanar, transitioning from a largely coronal orientation to a more prominent sagittal positioning. The orientation of each joint to the sagittal plane can also differ between the paired facet joints at the same spinal level. This phenomenon is known as tropism and has a 20–40% incidence among the general population.[24,50] Most[50–55] but not all[49,56] studies have demonstrated a positive relation between facet joint tropism and intervertebral disc degeneration and herniation.

Although most of the axial load is borne by the intervertebral discs, the two other components of the three-joint complex, the l-z joints, also play a role in weight bearing, with the proportion dependent on several factors. In a study by Yang and King,[57] the authors determined that normal facet joints typically carry 3–25% of the axial burden, which can increase even higher in patients with degenerative disc disease facet arthritis. During this seminal experiment, it was observed that with significant facet loading the inferior tip of the facets bottomed against the laminae below, functioning as pivots for the entire vertebral body to rotate backward. This resulted in considerable stretching of the superior facet capsules, manifesting as blood extravasating onto the outer surface of the capsule. In another cadaveric study, Adams and Hutton[58] found that the lumbar facet joints resist approximately 16% of the intervertebral compressive force when standing erect *versus* near 0% when sitting, which helps explain the high intradiscal pressures during unsupported sitting.[59] Finally, after conducting *in vitro* experiments measuring induced loads on cadaveric lumbar facets, Lorenz *et al.*[60] concluded that with increasing compressive loads, the absolute facet loads increases only slightly, so that the proportion of the axial burden borne by the l-z joints actually decreases with increasing stress. During extension, the normal load on the facet joints is always higher when compared with the neutral mode. After facetectomy, while the remaining load on the vestigial facet is substantially reduced, the peak pressure increases.[60] In summary, the l-z joints serve primarily a protective role, functioning to limit movement in all planes of motion. Whereas they do play a part in weight bearing, the proportion of the axial load they bear is inversely proportional to the amount of stress.

Mechanisms of Injury

Cadaveric and Animal Studies

Although in rare instances the development of facet joint arthropathy can be traced to a specific inciting event,[61] the overwhelming majority of cases of l-z joint pain are the result of repetitive strain and/or low-grade trauma accumulated over the course of a lifetime. Khalsa *et al.* conducted a series of cadaveric experiments designed to determine which physiologic movements are associated with the greatest degree of facet joint capsule strains. They found that the joint moments measured at any given motion increased with greater magnitudes of joint displacement, and were significantly larger in the two most caudad facet joints (L4–L5 and L5–S1).[62] With lateral bending, strains of the joint capsule tended to be larger in magnitude in the three most caudad joints (L3–S1) during contralateral flexion (*i.e.*, the left facet joints are most strained during right lateral flexion), whereas the two most cephalad joints (L1–L2 and L2–L3) bore the greatest strain during bending to the ipsilateral side. For the upper three facet joints, the maximum joint displacement and greatest strain was associated with lateral bending, usually to the right. For the two lowest joints, the greatest degree of strain occurred during forward flexion (table 1).

In a follow-up study, the authors fixated human lumbar spine specimens with a single anterior thoracolumbar plate on L4–L5, and then measured capsular displace-

Copyright © by the American Society of Anesthesiologists. Unauthorized reproduction of this article is prohibited.
Downloaded from http://pubs.asahq.org/anesthesiology/article-pdf/106/3/591/363690/0000542-200703000-00024.pdf by guest on 23 September 2024

Table 1. Motions Associated with the Largest Intervertebral Angulation and Strain for the Lumbar Facet Joints

Facet Joint Level	Movement Associated with Maximal IVA	Largest Strain
L1–L2	Right bending	Right bending
L2–L3	Left bending	Right bending
L3–L4	Right bending	Right bending
L4–L5	Forward flexion	Forward flexion
L5–S1	Extension	Forward flexion

IVA = intervertebral angle.
Modified from Ianuzzi *et al.*[62]

ment and strains for a wide range of physiologic motions.[63] For all motions, increased joint moments occurred at the level of fixation and both adjacent levels. There was also an increase in intervertebral angulation at L3–L4 and L5–S1, and decreased motion at L4–L5. Increased strain was noted bilaterally at L3–L4 and L5–S1, and contralaterally at L4–L5. On the side ipsilateral to the fixation, decreased strain was found at L4–L5. These findings support the work of other investigators demonstrating that fusing two vertebrae results in a transfer of motion previously occurring at the operated level to adjacent segments, particularly L5–S1, which in turn can lead to accelerated degeneration.[64–68]

In a subsequent study, Little and Khalsa[69] found that both sustained and repetitive lumbar flexion increased capsular motion and joint strain from L3–L4 to L5–S1, with creep developing more rapidly during sustained flexion than with repetitive movements. Interestingly, these parameters remained elevated even after a 20-min recovery period. Although these studies provide a theoretical framework for the development of microinjury associated with repetitive spine movements, cadavers cannot experience pain, and the viscoelastic material properties factored into computational cadaveric spine models may differ from those found in live patients.[70]

In response to repetitive strain and inflammation, the synovial l-z joints can fill with fluid and distend, resulting in pain from stretching the joint capsule.[71] Distension of the articular recesses can also compress the exiting nerve root in the neural foramen or spinal canal, especially when the foramen is already narrowed by joint hypertrophy and/or osteophytes. [72–75] This can lead to concomitant sciatica and mask the facet pathology underlying the radiculopathy. Capsular irritation may also result in reflex spasm of the erector spinae, multifidus, and other paraspinal muscles.[72,76,77]

In *in vivo* and *in vitro* experiments designed to reproduce facet capsular stretch, nerves typically cease firing shortly after the stimulus is removed.[78–80] Although these findings indicate that capsular strain could cause acute facetogenic pain, they do not explain its persistence. The pathophysiologic basis for persistent lumbar facet pain was established in a series of elegant experiments conducted by Cavanaugh, Yamashita, Ozaktay, *et al.* in New Zealand white rabbits. In these studies, the application of inflammatory chemicals or algesic mediators such as substance P and phospholipase A_2, were found to result in inflammatory changes consisting of vasodilation, venous congestion, and the accumulation of polymorphonuclear leukocytes. Neuronal sensitization occurred in both nociceptive and proprioceptive nerve endings, being manifested by reduced mechanical thresholds, increases in multiunit discharge rate and recruitment of previously silent units.[81–84] Persistent nociceptive input invariably leads to peripheral sensitization, and if the underlying stimulus is not removed, central sensitization and neuroplasticity can develop.[85] Whereas the spinal structures in humans are subject to greater stress than other mammals, because of the array of anatomical and functional differences that exist between the l-z joints in various mammalian species,[86] caution should be exercised when extrapolating the results of animal studies to humans.

One inferential interpretation of these preclinical findings is that chronic l-z joint pain is likely to occur with repetitive, chronic strains as might be seen in the elderly or, less frequently, after an acute event such as tearing the joint capsule by stretching it beyond its physiologic limits. This hypothesis is supported by clinical studies indicating a higher prevalence of facet arthropathy in elderly patients[87–89] and numerous cases of lumbar facet arthropathy after high-energy trauma.[61]

Human Studies

Clinically, several conditions may predispose individuals to chronic facet joint strain. Radiologic studies conducted in LBP patients and asymptomatic controls have shown a positive correlation between sagittally oriented facet joints and degenerative spondylolisthesis.[48,49] In these patients, recurrent rotational strains result in myriad changes to the discs and paired l-z joints, including loss of disc height, osteophyte formation, and degenerative hypertrophy of the facets.[90,91]

Changes in any component of the three-joint spinal unit lead to predictable changes in the other components. Degeneration and loss of structural integrity of the intervertebral discs have been shown to result in concomitant degenerative changes in the l-z joints.[92–94] The reverse is also true. Degeneration and motion abnormalities at the l-z joints can induce and accelerate degeneration of the intervertebral discs.[58,95,96] In a magnetic resonance imaging (MRI) study evaluating the relation between facet joint osteoarthritis and degenerative disc disease (DDD), Fujiwara *et al.* [97] found that facet joint osteoarthritis was rarely found in the absence of disc degeneration but tended to be most pronounced at spinal levels associated with advanced DDD. The authors concluded that disc degeneration is a more reliable indicator of aging

Copyright © by the American Society of Anesthesiologists. Unauthorized reproduction of this article is prohibited.
Downloaded from http://pubs.asahq.org/anesthesiology/article-pdf/106/3/591/363690/0000542-200703000-00024.pdf by guest on 23 September 2024

than facet joint osteoarthritis, and in most people, DDD precedes facet osteoarthritis.

Paradoxically, in the only clinical study evaluating the relative contributions of DDD and facet arthropathy to chronic LBP, Schwarzer *et al.*[98] found the combination of discogenic and l-z joint pain to be a relatively rare occurrence. In 92 patients who underwent both discography and confirmatory l-z joint blocks with lidocaine and bupivacaine, 39% had at least one positive discogram with a negative control disc, and 9% obtained concordant pain relief after the series of analgesic facet joint blocks. But only 3% of patients had both positive discography and a symptomatic l-z joint. The discrepancy between the handful of basic science studies demonstrating a correlation between DDD and facet joint degeneration and the lone clinical study finding minimal overlap between the two pain generators indicates that more research is needed on this topic.

Aside from osteoarthritis, several other conditions may affect the facet joints. These include inflammatory arthritides such as rheumatoid arthritis, ankylosing spondylitis and reactive arthritis,[99–101] synovial impingement, meniscoid entrapment, chondromalacia facetae, pseudogout, synovial inflammation, villonodular synovitis, and acute and chronic infection.[102–106] Intrafacetal synovial cysts can be a source of pain because of distension and pressure on adjacent pain-generating structures, calcification, and asymmetrical facet hypertrophy.[107–110] In a retrospective review of MRI scans in 303 consecutive patients with LBP, Doyle and Merrilees[111] found that 9.5% had facet joint synovial cysts, the large majority of which were located posteriorly. Trauma may also cause lumbar facetogenic pain. There are more than two dozen reported cases of lumbar facet dislocation after rapid deceleration injuries (*e.g.*, traffic accidents), most involving L5–S1.[61,112–115] The mechanism of injury in these cases is purported to be a combination of hyperflexion, distraction, and rotation.[61,112,116] In a posthumous study conducted in 31 lumbar spines of subjects who died of traumatic injuries (mostly motor vehicle accidents), Twomey *et al.*[117] found occult bony fractures in the superior articular process or subchondral bone plate in 35% of victims, and z-joint capsular and/or articular-cartilage damage in 77% of cases. The authors concluded that occult bony and soft tissue injuries to the l-z joints may be a common cause of LBP after trauma.

Prevalence

The prevalence rate of l-z joint pain varies widely in the literature, ranging from less than 5% to upward of 90%.[118–125] To a large extent, the wide discrepancy in prevalence rates is a function of the diagnostic methodology used and the perspective and conviction of the investigator. Numerous reviews have outlined the inherent flaws in diagnosing l-z joint pain using historic, physical examination, and radiologic findings and concluded that an analgesic response to image-guided intraarticular or MBB is the only reliable and valid method to identify a facet joint(s) as the primary pain generator.[126–128] Furthermore, the false-positive rate of uncontrolled facet blocks has been found to range between 25% and 41% using comparative LA injections or saline controls,[129–132] leading some experts to conclude that the use of controlled blocks is the only reliable means to diagnose lumbar facetogenic pain.[133]

Using single LA blocks, the prevalence of l-z joint pain has been reported to range from 8% to 94%.[89,119] When placebo-controlled and comparative LA facet blocks are used, the reported prevalence rates decline significantly, ranging from 9% to 42%.[98,131] The estimated prevalence rates increase in conjunction with age in the populations studied. In a comprehensive epidemiologic study on LBP, spine surgeons from eight academic medical centers in the United States collected demographic and clinical information on more than 4,000 patients during a 5-yr period.[118] Final diagnoses were rendered based on historic and physical examination findings, radiologic and other diagnostic studies, and response to treatment and/or diagnostic injections. Among the 2,374 patients who remained in the study, "facet joint arthritis" was the final diagnosis in 4.8% of cases. In an epidemiologic study conducted in a primary care setting, l-z joint pain was estimated to account for approximately 6% of patients with chronic LBP.[134] Based on studies using comparative or controlled blocks, in descending order, the L5–S1, L4–L5, and L3–L4 facet joints are most frequently implicated in l-z joint pain.[98,130,132]

One problem that emerges when synthesizing data from published prevalence studies is that almost all excluded patients with neurologic signs or symptoms secondary to a herniated disc, the most common cause of chronic LBP, and many excluded patients with previous back surgery. In patients with facet hypertrophy, foraminal narrowing can actually cause radicular symptoms.[72–74,135] A second confounding factor is that the best prevalence studies used comparative MBB to estimate l-z joint pain. The primary dorsal rami divide into three nerves as they approach their respective transverse processes, the largest of which is the medial branch. In addition to supplying two facet joints, the medial branch also innervates the multifidus, interspinales muscle and ligament, and the periosteum of the neural arch. The two other main branches of the dorsal ramus are the intermediate branch, which sends fibers into the longissimus muscle, and the lateral branch, which innervates the iliocostalis muscle, the thoracolumbar fascia, the skin of the lower back and buttock, and the sacroiliac joint.[29,136,137] At the superomedial border of the trans-

Copyright © by the American Society of Anesthesiologists. Unauthorized reproduction of this article is prohibited.
Downloaded from http://pubs.asahq.org/anesthesiology/article-pdf/106/3/591/363690/0000542-200703000-00024.pdf by guest on 23 September 2024

verse processes where the lumbar medial branches are most amenable to blockade, these nerves are in such close proximity that anesthetizing any one of them will almost invariably lead to blockade of the others branches of the primary dorsal rami. Therefore, MBB may not only block nociceptive signals arising from the l-z joints, but also from several other potential pain-generating structures around the lumbar spine. This makes the true prevalence rate of l-z joint pain exceedingly difficult to estimate. Based on the evidence that does exist, the lumbar facet joints seem to be the primary pain generator in approximately 10–15% of chronic LBP patients (table 2).

Pain Referral Patterns

In an attempt to better understand l-z joint pain, many investigators have attempted to identify pain referral patterns using a variety of different methods. These include pain provocation *via* stimulation of the facet joint capsules and medial branches in pain patients and asymptomatic volunteers, and mapping out pain diagrams in subjects in whom pain was relieved by the injection of LA, with or without steroid. For the most part, these studies have not demonstrated any reliable pain referral pattern stemming from any of the l-z joints. Discrepancies between pain provocation and pain patterns/histologic findings have been found not only for l-z joint stimulation,[138,139] but also during sacroiliac joint and selective nerve root blocks.[140,141] Part of the problem with using provocative tests to delineate pain referral patterns is that artificial stimulation of the l-z joints and/or their nerve supply may not simulate physiologic conditions.

Nevertheless, certain patterns do emerge when synthesizing the existing data. To summarize these findings, the joint capsule seems to be more likely to generate pain than the synovium or articular cartilage. There is also considerable overlap between all lumbar facet joints, with the referral pattern being more widespread and variable in patients with chronic pain than in asymptomatic volunteers. All of the lumbar facet joints are capable of producing pain that can be referred into the groin, although this is more common with lower facet joint pathology. Pain emanating from upper facet joints tends to extend into the flank, hip, and upper lateral thigh, whereas pain from the lower facet joints is likely to penetrate deeper into the thigh, usually laterally and/or posteriorly. Infrequently, the L4–L5 and L5–S1 facet joints can provoke pain extending into the lower lateral leg and, in rare instances, even the foot. In patients with osteophytes, synovial cysts, or facet hypertrophy, the presence of radicular symptoms may also accompany sclerotomal referral patterns (table 3 and fig. 4).

Diagnosis

History and Physical Examination

Numerous studies have attempted to delineate a discrete set of historic and physical findings pathognomonic or at least suggestive of lumbar facet arthropathy. Fairbank *et al.*[142] conducted a prospective study in 41 patients with acute LBP whereby two-level intraarticular facet blocks were performed with low-volume bupivacaine. Among the 25 patients who completed the study, 14 obtained at least temporary relief after the injections. Compared with nonresponders, responders tended to have pain localized to the back and thigh, and to report pain during forward flexion.

In 1988, Helbig and Lee[143] designated a "lumbar facet syndrome" based on a retrospective study conducted in 22 patients. The authors found that patients who responded to intraarticular facet injections (injection parameters not noted) were more likely to have back pain associated with groin or thigh pain, paraspinal tenderness, and reproduction of pain during extension–rotation maneuvers. Pain radiating below the knee was negatively associated with a positive response to facet blocks.

Despite the widespread acceptance of the "lumbar facet syndrome," a multitude of larger and more methodologically sound studies have failed to duplicate the findings of Helbig and Lee. In a large study conducted in 390 patients with chronic LBP, Jackson *et al.*[89] were unable to identify any historic or physical examination variables associated with analgesic response to facet injections. Schwarzer *et al.*[12] conducted a prospective study attempting to identify clinical features in 176 patients with chronic LBP undergoing double, confirmatory blocks. In the 15% of patients who achieved concordant pain relief with lidocaine and bupivacaine, no clinical feature was associated with a positive response. In a randomized, placebo-controlled study performed on 80 patients with chronic LBP, Revel *et al.*[88] identified seven variables associated with a positive response to facet joint anesthesia: age greater than 65 yr and pain not exacerbated by coughing, not worsened by hyperextension, not worsened by forward flexion, not worsened when rising from forward flexion, not worsened by extension–rotation, and well-relieved by recumbency. However, subsequent investigations have also failed to corroborate the findings of Revel *et al.* (table 4). In summary, no historic or physical examination findings can reliably predict response to diagnostic facet joint blocks.

Radiologic Findings

The prevalence of abnormal l-z joint changes on radiologic imaging depends on the age and presence of symptoms in the study population, the imaging modality used, and the threshold use for rendering a diagnosis of "ab-

Copyright © by the American Society of Anesthesiologists. Unauthorized reproduction of this article is prohibited.
Downloaded from http://pubs.asahq.org/anesthesiology/article-pdf/106/3/591/363690/0000542-200703000-00024.pdf by guest on 23 September 2024

Table 2. Results of Lumbar Zygapophysial Joint Pain Prevalence Studies Conducted Using Either Placebo-controlled or Comparative Local Anesthetic Blocks

Author, Year	Patients	Interventions	Results	False-positive Rate and Comments
Schwarzer *et al.*,[98] 1994	92 pts with chronic LBP without neurologic deficit or previous surgery. All pts underwent comparative facet blocks and provocative discography.	Pts rec'd either intraarticular (0.5 ml) or MBB (0.5 ml) with 2% lidocaine at 3 lowest facet levels. In pts who obtained ≥ 50% relief, blocks were repeated with 0.5% bupivacaine. A (+) response was pain relief sustained for ≥ 3 h.	39% of pts (n = 36) achieved definite pain relief after lidocaine blocks. 25% of pts who underwent confirmatory blocks with bupivacaine obtained had a (+) response, for a 9% prevalence rate.	26% rate of FP blocks. 39% of pts had (+) discography. Only 3 pts had both (+) discography and (+) response to facet blocks. Median age 37 yr. Male:female ratio was 2:1.
Schwarzer *et al.*,[130] 1994	176 pts with chronic LBP without neurologic deficit or previous surgery.	Pts rec'd either intraarticular or MBB (0.5 ml) with 2% lidocaine at 3 lowest levels. In pts who obtained ≥ 50% pain relief, blocks were repeated with 0.5% bupivacaine. A (+) response was pain relief sustained for ≥ 3 h.	47% of pts (n = 83) reported a definite or greater response after lidocaine, with 26 of 71 pts who underwent confirmatory blocks obtaining concordant relief, for a prevalence rate of 15%.	FP rate of 38%. Median age 38 yr.
Schwarzer *et al.*,[132] 1995	63 pts with chronic LBP without neurologic deficit or previous surgery.	Pts rec'd placebo injections followed by single-level intraarticular facet injections (up to 1.5 ml bupivacaine, 0.5%) at 3 lowest levels, on separate occasions. A (+) response was pain relief sustained for ≥ 3 h only with bupivacaine.	40% obtained > 50% pain relief with bupivacaine but not placebo. 37% had > 90% pain relief.	32% of pts obtained > 50% pain relief for ≥ 3 h after placebo. 18 of 23 obtained relief at only 1 level. Median age 59 yr. Female:male ratio was 3:1.
Revel *et al.*,[88] 1998	80 pts with chronic LBP not due to sciatica, without previous surgery.	Pts rec'd either placebo or 1 ml lidocaine injected into the 2 most caudad facet joints. A (+) response was > 75% pain relief.	31% of lidocaine group obtained significant pain relief after the injection.	18% of pts receiving intraarticular saline obtained significant pain relief. Mean age 58 yr. 2:1 female:male ratio.
Manchikanti *et al.*,[131] 1999	120 pts with chronic LBP without neurologic deficit.	Pts rec'd MBB with 0.4–0.6 ml of 1% lidocaine and/or 0.25% bupivacaine. A (+) response was ≥ 75% relief lasting longer with bupivacaine than lidocaine.	81 pts (67.5%) reported a definite response to lidocaine MBB. 54 of these reported definite pain relief after the bupivacaine block, for a prevalence rate of 45%.	FP rate was 41%. Pts who had previous surgery were less likely to have l-z joint pain. Trauma was implicated as cause of pain in 53% of pts. Mean age 47 yr.
Manchikanti *et al.*,[129] 2000	180 pts with chronic LBP without neurologic deficits.	Pts rec'd double MBB from L1–L5 with 0.5 ml lidocaine and bupivacaine, LA with Sarapin (High Chemical, Levitown, PA), or LA with Sarapin and steroid. A (+) response was ≥ 75% relief lasting longer with bupivacaine than lidocaine.	74% of pts (n = 133) obtained a (+) response to the lidocaine blocks, but only 65 reported definite pain relief after bupivacaine blocks, for a 36% prevalence rate.	25% FP rate. Mean age was 48 yr.
Dreyfuss *et al.*,[182] 2000	41 carefully chosen pts out of 138 screened by telephone interview with chronic LBP, no neurologic deficits, and an absence of psychiatric or severe concomitant spinal pathology.	Pts rec'd MBB with 2% lidocaine at maximally tender areas. Pts who obtained ≥ 80% pain relief underwent confirmatory blocks with bupivacaine. A (+) response was definite pain relief lasting > 2 h.	22 pts obtained significant pain relief after lidocaine MBB, with 15 obtaining ≥ 80% after bupivacaine blocks, for a 37% prevalence rate.	FP rate of 17%. Mean age 55 yr in 15 responders. Pts carefully chosen to evaluate outcomes for radiofrequency denervation.
Manchikanti *et al.*,[266] 2000	200 pts with chronic LBP without neurologic deficits.	Pts rec'd MBB with 1% lidocaine. All pts who obtained ≥ 75% pain relief underwent confirmatory blocks with 0.25% bupivacaine. A (+) response was ≥ 75% relief lasting longer with bupivacaine.	64% (n = 127) reported a (+) response to lidocaine blocks, with 84 obtaining definite pain relief after bupivacaine blocks, for a 42% prevalence rate.	37% FP rate. Mean age 47 yr.
Manchikanti *et al.*,[267] 2004	397 pts with chronic LBP without neurologic deficits.	Pts rec'd MBB with 1% lidocaine. All pts who obtained ≥ 75% pain relief underwent confirmatory blocks with 0.25% bupivacaine. A (+) response was ≥ 80% relief lasting longer with bupivacaine.	198 (50%) of pts obtained a (+) response to lidocaine blocks, with 124 reporting definite pain relief with bupivacaine, for a 31% prevalence rate.	FP rate was 27%. Mean age 47 yr.

False-positive (FP) rate: If not mentioned, this was determined by dividing the number of patients who obtained pain relief with the lidocaine screening block but not by the confirmatory block by the total number of blocks.

LA = local anesthetic; LBP = low back pain; MBB = medial branch block; pts = patients; rec'd = received.

normal" (table 5). In studies conducted in patients with LBP, the incidence of degenerative facet disease on computed tomographic (CT) scanning ranges from around 40% in some studies[125,144] to upwards of 85% in others.[119] MRI is considered to be somewhat less sensitive than CT imaging for detecting degenerative facet changes,[119,145,146] although several studies conducted in chronic LBP patients found both the sensitivity and spec-

Copyright © by the American Society of Anesthesiologists. Unauthorized reproduction of this article is prohibited.

Downloaded from http://pubs.asahq.org/anesthesiology/article-pdf/106/3/591/363690/0000542-200703000-00024.pdf by guest on 23 September 2024

Table 3. Results of Studies Examining PAIN referral Patterns for Lumbar Zygapophysial Joint Pain

Author, Year	Patients and Interventions	Results
Hirsch *et al.*,[7] 1963	Number of pts and characteristics not mentioned. Injected < 0.3 ml hypertonic NS, 11%, into one of the lower facet joints.	Pain distributed to SI joint and gluteal areas, then out to greater trochanter. Pain identical to typical LBP.
Mooney and Robertson,[9] 1976	5 controls and 15 pts with chronic LBP. Injected 1–3 ml hypertonic NS, 5%, into L3–L4 through L5–S1 facet joints, and S1–S2 in pts with lumbarization of the sacrum.	L3–L4 produced pain radiating down lateral aspect of leg. L4–L5 and L5–S1 produced pain radiating posteriorly down the leg, often below the knee in pts with LBP. If present, S1–S2 produced pain radiating under buttock. Increasing volume increased amount of radiation. Pts with LBP had greater radiation than pts without back pain.
McCall *et al.*,[10] 1979	Injected 0.4 ml hypertonic saline, 6%, intracapsular and pericapsular, into the L1–L2 and L4–L5 facet joints of 6 asymptomatic male volunteers.	There was little difference in pain distribution between intracapsular and pericapsular injections. Pain from L4–L5 radiated to the flank, buttock, iliac crest, upper and lower groin, and thigh above the knee. Pain from L1–L2 radiated to the flank, iliac crest, upper groin, and occasionally the abdomen. Pain never radiated contralaterally.
Fairbank *et al.*,[142] 1981	25 pts with acute back and/or leg pain underwent l-z joint injections at the area of maximal tenderness and 1 additional randomly chosen joint with 0.5 ml bupivacaine.	Responders had pain in the back and thigh, whereas nonresponders had pain in back and lower leg. Symptomatic pain reproduction occurred only in 6 pts.
Lippitt,[205] 1984	Retrospective review of 99 pts with LBP of varying duration who underwent l-z joint injections with 1 ml lidocaine and steroid.	No pattern of pain was noted to be more common in responders. Included pts with unilateral or bilateral hip pain, buttock pain, or pain localized to low back.
Lynch and Taylor,[268] 1986	50 pts with chronic LBP diagnosed by physical examination and x-rays as having facet pain underwent intraarticular steroid injections in 1 or 2 lower facet joints.	39 pts reported total (n = 11) or partial (n = 28) relief of pain after 2 wk. More than 90% of pts reported LBP during injection, with half reporting pain radiating into ipsilateral thigh and buttock. No pt reported pain below knee.
Helbig and Lee,[143] 1988	Retrospective review of 22 pts with chronic low back and leg pain. Injected l-z joint(s) with LA and steroid. Divided pts into (−) response (no relief), temporary response (relief lasted > a few h but < 6 mo), and prolonged response (> 6 mo relief).	80% of pts with groin or thigh pain had a prolonged response. No pt with groin pain and only 1 with thigh pain had (−) response. Pts with pain below knee had 37% (−) responses and only 25% prolonged responses.
Jackson *et al.*,[89] 1988	390 pts with low back and no neurologic signs underwent L4–L5 and L5–S1 l-z joint injections with steroid and 1 ml bupivacaine.	Postinjection pain relief was more likely to occur in patients without leg pain.
Marks *et al.*,[269] 1989	138 pts with chronic LBP underwent lumbar facet and MBB at the same levels. Blocks performed with 1.0 ml lidocaine, except at L5–S1, where 1.5 ml was used.	The pain produced at all levels was mostly local. The L4–L5 and L5–S1 joints were also likely to radiate to buttock, greater trochanter, and all aspects of thigh. Approximately 5% of time, pain extended below knee. Pain from L2–L5 sometimes extended to groin. Stimulation of nerves was more likely to produce distally referred pain than intraarticular provocation.
Kuslich *et al.*,[11] 1991	193 pts undergoing decompression surgery during local anesthesia. Stimulated a variety of tissue, included l-z joints by mechanical force or unipolar cautery.	Facet capsule stimulation produced pain in 30% of pts, but "significant pain" only 2.5% of time. Pain radiated into back and buttock, but never the leg.
Marks,[8] 1992	86 pts with chronic LBP receive either l-z joint or MBB with steroid and 1 or 1.5 (at L5–S1 or the L5 dorsal ramus) ml LA.	No pattern of pain predicted response to injection. Pts were included who had axial pain and pain radiating to the leg.
Schwarzer *et al.*,[139] 1994	90 pts with chronic LBP underwent l-z joint blocks with 0.8 ml contrast and lidocaine at 3 levels.	Based on analgesic response to a single block, there was a significant association between concordant pain provocation and pain relief. However, based on concordant analgesic response to serial lidocaine and bupivacaine blocks, there was no association between pain provocation and pain relief.
Fukui *et al.*,[270] 1997	48 pts with chronic LBP underwent l-z joint blocks with contrast until pain was provoked, then rec'd 0.5–1 ml LA. Pts who obtained excellent but temporary relief proceeded to RF denervation, with electrical stimulation used to locate the target nerve.	Intraarticular contrast injection always reproduced a pt's pain. Pain from L1–L2 joint always produced lumbar pain. In descending order, L2–L3 joint produced pain in the lumbar region, hip, and buttock or lateral thigh. L3–L4 produced pain mostly in the lumbar region, buttock, or lateral/posterior thigh. L4–L5 elicited pain in the lumbar region, buttock, or lateral thigh. L5–S1 elicited pain in the lumbar region, buttock, lateral thigh, or posterior thigh. Pain relief from stimulation of medial branches was similar to that of l-z joints.
Kaplan *et al.*,[32] 1998	15 asymptomatic pts underwent painful facet capsular distension with up to 2.5 ml contrast.	All subjects experienced a well-circumscribed area of pain without radiation into the inferior buttock or extremity.
Manchikanti *et al.*,[131] 1999	120 pts with chronic LBP and no neurologic deficits underwent confirmatory MBB with 0.4–0.6 ml lidocaine and bupivacaine.	No pattern of pain predicted response to injection. Pts were included who had axial pain only, thigh pain, groin pain, and leg pain.
Manchikanti *et al.*,[266] 2000	200 pts with chronic LBP without neurologic deficits underwent confirmatory MBB with 0.4–0.6 ml lidocaine and bupivacaine.	No pattern of pain predicted response to injection. Pts were included who had axial pain only, thigh pain, groin pain, and/or leg pain.
Young *et al.*,[271] 2003	23 pts with chronic LBP and no neurologic deficits underwent l-z joint injections with < 1.5 ml LA. A (+) response was designated as both concordant pain provocation and relief with LA.	The location of pain (radiating toward or away from the spinal column) was not associated with a (+) response.

LA = local anesthetic; LBP = low back pain; l-z = lumbar zygapophysial; MBB = medial branch block; NS = normal saline; pts = patients; rec'd = received; RF = radiofrequency; SI = sacroiliac.

Copyright © by the American Society of Anesthesiologists. Unauthorized reproduction of this article is prohibited.

Downloaded from http://pubs.asahq.org/anesthesiology/article-pdf/106/3/591/363690/0000542-200703000-00024.pdf by guest on 23 September 2024

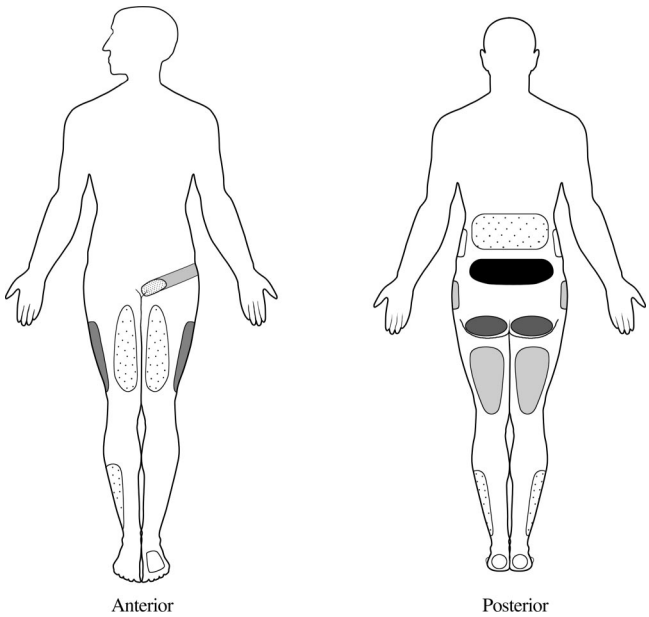

Fig. 4. Pain referral patterns from the lumbar facet joints. In descending order, the most common referral patterns extend from the *darkest* (low back) to the *lightest* regions (flank and foot). The *key* at the bottom of the figure legend is listed in order of affected frequency (*i.e.*, low back to foot). The *facet levels* next to each location represent the zygapophysial joints associated with pain in each region. Data adapted from McCall *et al.*,[10] Marks,[269] and Fukui *et al.*[270] Drawings by Specialist Frank and Angela Dill, US Army, and Frank M. Cort, M.S. (Research Associate, Department of Radiology, Johns Hopkins Hospital, Baltimore, Maryland). Low back: L5–S1, L4–L5, L3–L4 Buttock: L5–S1, L4–L5, L3–L4 Lateral thigh: L5–S1, L4–L5, L3–L4, L2–L3 Posterior thigh: L5–S1, L4–L5, L3–L4 Greater trochanter: L5–S1, L4–L5, L3–L4, L2–L3 Groin: L5–S1, L4–L5, L3–L4, L2–L3, L1–L2 Anterior thigh: L5–S1, L4–L5, L3–L4 Lateral lower leg: L5–S1, L4–L5, L3–L4 Upper back: L3–L4, L2–L3, L1–L2 Flank: L1–L2, L2–L3 Foot: L5–S1, L4–L5

ificity of MRI to be more than 90% compared with CT.[97,145] In a study by Fujiwara *et al.*[97] conducted in 14 subjects with DDD, the extent of lumbar facet osteoarthritic changes was minimal in patients younger than 40 yr. In patients older than 60 yr, the prevalence of degenerative changes increased significantly but was by no means universal. No facet osteoarthritis was observed in any patient in the absence of disc degeneration. In CT and MRI studies conducted in asymptomatic volunteers, the prevalence of facet degeneration ranges from 8% to 14%.[147–149] In one study by Weishaupt *et al.*[147] conducted in 60 asymptomatic volunteers aged 20–50 yr, disc bulging or protrusion was found in 37 and 40 subjects, but severe osteoarthritis of the facet joints was absent in all 60 subjects. The authors suggested that severe osteoarthritis of the l-z joints may play a prominent role in LBP because of its absence in asymptomatic individuals.

The ability of radiologic imaging to predict response to diagnostic l-z joint blocks has been conflicting at best. Whereas some studies have found a positive correlation between CT, MRI, or other imaging studies and response to l-z joint blocks,[124,125,143,144,150] an equal number have not.[87,89,119,142,151,152] Results from the three largest studies have also been mixed. The largest study, by Jackson *et al.*,[89] found no relation between radiographic evidence of l-z joint degeneration and response to single, intraarticular facet injections in 390 patients. This is in contrast to Carrera and Williams,[144] who found that 73% of chronic LBP patients (n = 63) demonstrating CT evidence of lumbar facet disease experienced pain relief after large-volume (2–4 ml) facet blocks *versus* only 13% in whom CT scans showed no pathology. In the only study using placebo-controlled blocks to confirm a diagnosis of l-z joint pain, Schwarzer *et al.*[152] found no correlation between CT findings and a positive response to LA but not saline blocks in 63 patients. The results of Jackson *et al.* and Schwarzer *et al.* support clinical studies showing no correlation between MRI findings and results of medial branch radiofrequency denervation. In a study by Cohen *et al.*[153] conducted in 192 patients who underwent radiofrequency denervation based on a positive response to single MBB, the authors found no association between MRI evidence of facet hypertrophy or degeneration and 6-month outcomes. Finally, Kawaguchi *et al.*[154] found no significant association between the degree of radiographic lumbar facet joint abnormalities and LBP symptoms in a study conducted in 106 patients with rheumatoid arthritis. In summary, the evidence in the literature does not support the routine use of radiologic imaging to diagnose l-z joint pain.

Diagnostic Blocks

It is generally accepted in clinical practice that diagnostic blocks are the most reliable means for diagnosing l-z joints as pain generators. Numerous guidelines and reviews have asserted that intraarticular injections and MBB are equally effective in diagnosing l-z joint pain.[105,126,127,133] Although this statement may seem to have face validity, several factors may undermine the utility of diagnostic blocks, especially MBB. In a cadaveric study, Kellegren[155] showed that 0.5 ml injectate spread into an area encompassing 6 cm^2 of tissue. In view of the close proximity of the medial branch nerves to the lateral and intermediate branches, even the injection of a low-volume of anesthetic is likely to block these nerves. Because these nerves, along with the medial branches themselves, contribute heavily to the innervation of the paraspinal muscles and fascia, ligaments, sacroiliac joints, and skin, MBB can relieve LBP even in the presence of normal l-z joints.

Whereas properly performed intraarticular facet injections may be inherently more accurate in diagnosing l-z joint pain, these blocks can be technically challenging and fraught with their own limitations. After injecting somewhere between 1 and 2 ml of fluid, the joint capsule is likely to rupture, with the excess injectate extrav-

Copyright © by the American Society of Anesthesiologists. Unauthorized reproduction of this article is prohibited.
Downloaded from http://pubs.asahq.org/anesthesiology/article-pdf/106/3/591/363690/0000542-200703000-00024.pdf by guest on 23 September 2024

Table 4. Studies Evaluating the Ability of Historic and Physical Examination Findings to Predict Response to Diagnostic Lumbar Facet Injections

Author, Year	Patients and Interventions	Results	Comments
Fairbank *et al.*,[142] 1981	25 pts with acute LBP rec'd intraarticular facet injections at 2 levels with 0.5 ml LA.	Responders had pain localized to back and thigh, whereas nonresponders had pain in lower leg. Responders tended to report more pain during forward flexion.	8 pts obtained relief lasting 1–48 h, and 6 obtained long-term relief. No difference between groups in duration of sx, disability scores, or psychological profile.
Helbig and Lee,[143] 1988	Retrospective study conducted in 22 pts with LBP and leg pain. Injection parameters not noted.	Back pain radiating to groin or thigh, paraspinal tenderness, and reproduction of pain with extension–rotation associated with (+) response. Pain extending below knee associated with (−) response.	23% of pts had a negative response, 27% had a temporary response, and 50% a prolonged response.
Lewinnek and Warfield,[124] 1986	Retrospective study conducted in 21 pts. Intraarticular injections performed with LA and steroid.	Negative screening examination for other causes of LBP or sciatica and paraspinal tenderness over one or more facet joints associated with (+) response.	75% of pts had an initial (+) response, but only 33% had a response lasting > 3 mo.
Jackson *et al.*,[89] 1988	390 pts with LBP underwent intraarticular LA and steroid injections at L4–L5 and L5–S1 with 1.5 ml.	Unable to identify a "facet syndrome." Factors associated with a (+) response were older age, absence of leg pain, and absence of pain with Valsalva.	7.7% reported complete pain relief after injection.
Lilius *et al.*,[272] 1990	109 pts with unilateral chronic LBP were randomly assigned to receive either 8 ml LA and steroid into 2 facet joints, around 2 facet joints, or NS into 2 facet joints.	No clinical finding was associated with outcome. The number of "inappropriate signs or sx" and previous back surgery were positively associated with failure.	Approximately 30% of pts showed significant improvement. Pain relief at 1 h after injection correlated with pain relief at 3 mo after injection. No basis for large volumes injected.
Revel *et al.*,[87] 1992	40 pts with chronic LBP underwent intraarticular facet injections with 1.5 ml LA.	Factors associated with a (+) response were older age, absence of pain exacerbation by coughing, relief when recumbent, absence of exacerbation by forward flexion and rising from forward flexion, absence of exacerbation by hyperextension, and absence of exacerbation by extension–rotation.	55% had (+) response to injection, of which 43% had > 90% relief.
Schwarzer *et al.*,[130] 1994	176 pts with chronic LBP underwent confirmatory medial branch or facet blocks with 0.5 ml LA.	No statistically significant association between response to blocks found for any feature on history or PE.	15% responded with concordant relief to lidocaine and confirmatory bupivacaine blocks.
Schwarzer *et al.*,[132] 1995	63 pts with chronic LBP underwent intraarticular facet injections with LA and NS.	No historic PE finding could distinguish pts with (+) response to blocks.	40% of pts obtained significant relief with LA but not NS.
Revel *et al.*,[88] 1998	80 pts with chronic LBP underwent intraarticular facet injections with 1 ml LA or NS.	Factors associated with a (+) response were older age, absence of pain exacerbation by coughing, relief when recumbent, absence of exacerbation by forward flexion and rising from forward flexion, absence of exacerbation by hyperextension, and absence of exacerbation by extension–rotation.	Results identical to previous uncontrolled study. Presence of 5 of 7 variables distinguished 92% of responders and 80% of nonresponders.
Manchikanti *et al.*,[131] 1999	120 pts with chronic LBP underwent confirmatory MBB with 0.4–0.6 ml LA.	Only historic or PE finding associated with a (+) response was absence of back pain with straight leg raising.	45% of pts had a concordant (+) response to lidocaine and bupivacaine blocks.
Manchikanti *et al.*,[129] 2000	180 pts with chronic LBP underwent confirmatory MBB with 0.4–0.6 ml LA mixed with or without Sarapin (High Chemical, Levitown, PA) and steroid.	Only historic or PE finding associated with a (+) response was absence of back or leg pain with straight leg raising.	36% had a concordant (+) response to both blocks.
Manchikanti *et al.*,[266] 2000	200 pts with chronic LBP underwent confirmatory MBB with 0.4–0.6 ml LA.	Only clinical feature associated with (+) response was relief of pain in supine position. Negative correlation between exacerbation of back pain with straight leg raising and (+) block.	42% prevalence rate. Negative correlation between previous surgery and positive response to blocks.
Young *et al.*,[271] 2003	23 pts with chronic LBP underwent intraarticular facet injections with < 1.5 ml LA.	Only lack of pain provocation when rising from sitting was associated with (+) response.	61% of pts experienced concordant pain during injection and relief after LA instillation.
Laslett *et al.*,[273] 2004	111 pts underwent intraarticular or MBB with 0.5 ml LA. Study designed to confirm Revel's findings.[88]	Only absence of pain with coughing and absence of pain exacerbation when rising from flexion showed a trend toward being associated with a (+) response ($P = 0.07$).	23% of pts obtained ≥ 75% pain relief after block. Pts older than 65 yr were more likely to obtain complete pain relief.
Laslett *et al.*,[274] 2006	151 pts underwent confirmatory MBB or intraarticular injections with 0.5 ml LA.	Factors associated with (+) response were age > 50 yr, pain relieved by walking, pain relieved by sitting, onset of pain was paraspinal, high somatization score, pain worsened by extension–rotation, and absence of "centralization" of pain.	31 pts excluded. Data missing in many pts. Utility of predictive factors diminished with decreasing pain reduction standards.

LA = local anesthetic; LBP = low back pain; MBB = medial branch block; NS = normal saline; PE = physical examination; pts = patients; rec'd = received; sx = symptoms.

Copyright © by the American Society of Anesthesiologists. Unauthorized reproduction of this article is prohibited.

Downloaded from http://pubs.asahq.org/anesthesiology/article-pdf/106/3/591/363690/0000542-200703000-00024.pdf by guest on 23 September 2024

Table 5. Levels of Degeneration of Facet Joints based on Magnetic Resonance Imaging

Grade	Radiologic Findings
0	Normal z-joints (2–4 mm width)
1	Joint space narrowing and/or mild osteophyte formation and/or mild hypertrophy of the articular process
2	Narrowing of the joint space with sclerosis or moderate osteophyte formation and/or moderate hypertrophy of the articular process and/or mild subarticular bone erosions
3	Narrowing of the joint space with marked osteophyte formation and/or severe hypertrophy of the articular process and/or severe subarticular bone erosions and/or subchondral cysts

Adapted from Weishaupt *et al.*[145]; used with permission.

asating into several possible pain-generating structures. Depending on the point of rupture, these structures may include the epidural space, intervertebral foramen, ligamentum flavum, and paraspinal musculature.[8,71,122,123]

There are no crossover studies comparing the validity of MBB to intraarticular l-z joint injections, and only two studies comparing them at all. Nash[156] conducted a prospective study in 67 patients with axial LBP who were randomly assigned in pairs to receive either MBB with 2 ml LA or intraarticular injections with 1.5 ml LA and steroid. In the 26 pairs who completed the study, 12 reported MBB to be more beneficial at their 1-month follow-up, 11 reported the intraarticular injection to be better, and 3 reported no difference between the two. In the second study, Marks *et al.*[8] randomly assigned 86 axial LBP patients to receive either intraarticular injections or MBB using 2 ml LA and steroid. The authors found no difference in the immediate response between the two groups, although the intraarticular group experienced better pain relief at their 1-month but not 3-month follow-up. There are numerous flaws with these studies that limit the conclusions one can draw on the comparative validity of these two procedures, with the main one being the lack of a definitive diagnosis in the study subjects. Based on prevalence and false-positive rates in chronic LBP patients (table 2), MBB and intraarticular seem to provide comparable diagnostic value. In the four placebo-controlled studies evaluating radiofrequency denervation outcomes in patients with "confirmed" l-z joint pain, the only study that screened patients with MBB demonstrated positive outcomes,[157] *versus* only one of three that used diagnostic intraarticular injections.[158–160] Ultrasound-guided medial branch and intraarticular blocks have also been demonstrated to provide comparable accuracy to fluoroscopically guided injections, although they may be less likely to detect low-volume intravascular uptake and are less accurate in obese patients.[161–164] Because MBB are technically easier to perform than intraarticular injections and involve anesthetization of the nerves to be lesioned, it seems more logical to use these blocks as a prognostic tool before radiofrequency denervation.

False-positive Blocks

Numerous studies have documented a high false-positive rate for lumbar facet blocks, ranging from 25% to 40% using comparative blocks or saline controls (table 2).[128–130] This rate seems to be unaffected by the type of block used (*i.e.*, intraarticular or MBB). In a study evaluating the utility of comparative LA MBB *versus* placebo-controlled MBB to diagnose cervical z-joint, Lord *et al.*[165] found that the use of serial blocks with two different LA had a high degree of specificity (88%) but only marginal sensitivity (54%). In addition to the anatomical differences between cervical and lumbar facet joints, this study used the stringent criterion of "complete or profound pain relief" as the benchmark for a positive block, leaving the question of extrapolation subject to debate. However, one interpretation of these findings is that comparative, LA blocks predispose patients to false-negative diagnoses.

The reasons for false-positive facet blocks are multifactorial and include placebo response (18–32%) to diagnostic facet interventions, use of sedation, the liberal use of superficial LA, and the spread of injectate to pain-generating structures other than those targeted.[166] Although some investigators have disputed this assertion,[167,168] it is our belief that not only opioids, but sedatives such as midazolam, can lead to false-positive blocks by interfering with the interpretation of analgesic response (*i.e.*, preventing a patient from engaging in normal activities) and virtue of their muscle relaxant properties.[169] In a recent survey conducted in 500 patients receiving facet blocks or epidurals at an outpatient spine center, only 17% requested sedation.[170]

Even in patients with symptomatology concordant with unambiguous pathology, diagnostic blocks may lack specificity. North *et al.*[171] conducted a prospective study in 33 patients with L5 or S1 radiculopathy and radiologic evidence of ongoing nerve root compression. All patients underwent a battery of LA blocks that included selective nerve root block, sciatic nerve block, MBB, and subcutaneous control injections. The authors found that approximately 90% of patients obtained almost complete pain relief after the selective nerve root block, 70% obtained almost complete relief after the sciatic block, and a majority received at least 50% pain relief after the MBB. In contrast, the median degree of pain relief after the subcutaneous injection was around 30%. The authors concluded that uncontrolled LA blocks lack specificity in the diagnostic evaluation of referred pain syndromes.

Dreyfuss *et al.*[31] attempted to measure the specificity of lumbar MBB by performing 120 fluoroscopically guided injections in healthy volunteers using 0.5 ml injectate and identifying the contrast spread using CT

Copyright © by the American Society of Anesthesiologists. Unauthorized reproduction of this article is prohibited.
Downloaded from http://pubs.asahq.org/anesthesiology/article-pdf/106/3/591/363690/0000542-200703000-00024.pdf by guest on 23 September 2024

scan. Two target points were chosen, one at the superomedial border of the transverse process and a second lower site midway between the upper border of the transverse process and the mamilloaccessory ligament. Aberrant contrast was noted to spread into the intervertebral foramen or epidural space 16% of the time, being more common at cephalad spinal levels. When the lower target points were used, spread into adjacent neural structures only occurred when a needle was inadvertently placed too high. In all cases, distal spread was noted into the cleavage plane between the multifidus and longissimus muscles. In no instance did the 0.5 ml of contrast fail to bathe the target. The investigators concluded that lower volumes may be adequate for MBB and that using the lower target point may increase the specificity of lumbar MBB.

Following up on the Dreyfuss study, Cohen *et al.*[135] sought to determine whether spread into the epidural space or intervertebral foramina could account for false-positive MBB by examining the relation between clinical signs of radiculopathy, discographic findings, and radiofrequency outcomes in 78 patients with positive MBB who went on to fail radiofrequency denervation. The authors found a negative correlation between discogenic pain and failed radiofrequency denervation and no association between radicular pain and radiofrequency treatment outcomes. In contrast, there was a trend toward patients with failed back surgery syndrome to have a negative outcome after radiofrequency lesioning. The authors concluded that myofascial pain might be a significant cause of false-positive MBB.

The evidence that the inadvertent treatment of myofascial pain may be a significant cause of false-positive MBB is circumstantial, but multifaceted. In their large, multicenter epidemiologic study involving more than 2,000 patients, Long *et al.*[118] found myofascial pain to be the second most common cause of chronic LBP after herniated disc. Controlled studies conducted in chronic LBP patients have shown efficacy for both muscle relaxants and low-volume botulinum toxin injections, and electromyographic evidence of increased activity compared with matched controls.[172–175] Finally, Ackerman *et al.*[176] tested the hypothesis as to whether myofascial pain could account for the high rate of false-positive facet blocks in a double-blind study conducted in 75 men with chronic LBP. Subjects received either intraarticular facet injections or MBB using two techniques: one in which LA was used to provide superficial anesthesia down to the target point, and a second in which saline was injected as the needle was advanced. The authors found that the incidence of postprocedure pain relief was significantly higher in patients who had LA injected into their musculature than in those who received saline injected superficially. The injection of LA into the skin and soft tissues may also reduce LBP by means other than the inadvertent treatment of myofascial pain. In studies by Woolf *et al.*,[177,178] the authors found that the superficial injection of even very small amounts of lidocaine reduced nociceptive behavior in animal models of neuropathic pain, a finding attributed to the systemic absorption of the sodium channel blocker (table 6).

Table 6. Interventions That May Reduce the Incidence of False-positive Facet Blocks

1. Perform placebo-controlled blocks, or if not possible, comparative local anesthetic blocks.
2. Aim for a lower target point on the transverse process.
3. Reduce injectate volume to < 0.5 ml.
4. Be judicious with the use of superficial anesthesia.
5. Consider a single-needle approach.
6. Consider using computed tomographic guidance when doing intraarticular injections in patients with severe spondylosis.
7. Avoid the use of sedation or intravenous opioids.

To reduce the amount of superficial anesthesia used for MBB, Stojanovic *et al.*[179] introduced the single-needle technique whereby multiple medial branches are blocked using a single skin entry point. In a prospective, crossover study comparing the single-needle and conventional multiple-needle techniques, the authors found the single-needle technique required significantly less superficial LA, resulted in less procedure-related pain, and was quicker to perform than the multiple-needle approach.[180] With regard to final needle position, contrast spread, and postprocedure pain relief, no differences were noted between the two techniques.

False-negative Blocks

False-negative blocks may also occur during diagnostic facet injections. In a study by Kaplan *et al.*[32] conducted in 18 asymptomatic volunteers, the authors found that properly performed MBB result in failure to anesthetize the corresponding facet joint 11% of the time, even with the avoidance of venous uptake. Although this may have occurred because the LA did not engulf the target nerve, a more likely cause for the false-negative rate is the presence of aberrant or additional innervation to facet joints aside from medial branches. In the same study, the authors found inadvertent venous uptake occurred during 33% of nerve blocks. When the needle was repositioned to avoid venous uptake, analgesia was achieved only 50% of the time. The authors concluded that when venous uptake occurs, it may be advantageous to repeat the procedure on a separate occasion rather than redirecting the needle to avoid false-negative results. In a CT study by Dreyfuss *et al.*,[31] the authors found inadvertent venous uptake occurred only 8% of the time.

Should Single or Double Diagnostic Blocks Be Used?

The high rate of false-positive facet blocks has led numerous experts to advocate performing double blocks, using either saline controls or two different LA, before proceeding to definitive therapy.[12,128,130–133,181]

Copyright © by the American Society of Anesthesiologists. Unauthorized reproduction of this article is prohibited.
Downloaded from http://pubs.asahq.org/anesthesiology/article-pdf/106/3/591/363690/0000542-200703000-00024.pdf by guest on 23 September 2024

However, this is rarely done in clinical practice or controlled outcome studies, and there are currently no studies comparing outcomes using single and double blocks. In the only uncontrolled study assessing outcomes for medial branch radiofrequency denervation after comparative LA blocks, Dreyfuss *et al.*[182] found that 60% of the 15 patients who proceeded to radiofrequency lesioning achieved at least 90% pain relief at 12 months, and 87% achieved at least 60% relief. The basis for undergoing treatment was at least 80% concordant pain relief after lidocaine and bupivacaine MBB. However, 460 patients were interviewed for this study, and after history, physical examination, and record review, only 41 patients were chosen to participate. Had single blocks or less stringent criteria been used to designate radiofrequency candidates, the success rate would have indubitably been lower in this study, but the total number of successful treatments would have almost certainly been higher.

When considering whether to perform double blocks, several factors must be considered, including the patient's relative risk for a false-positive block, the complication rate of the diagnostic and definitive procedure (*i.e.*, radiofrequency denervation), the false-negative rate of diagnostic injections, and the cost effectiveness, including dropout rate, of performing an additional diagnostic injection. With the exception of a very low (< 5%) incidence of neuritis[183] that can be reduced even further with the preemptive use of steroid or pentoxifylline,[184] the complication rate is similar for diagnostic facet blocks and radiofrequency denervation. In a systematic study of the cost-effectiveness of using controlled facet blocks, Bogduk and Holmes[185] determined that the use of placebo-controlled injections cannot be justified in the United States based on financial considerations. Considering that a substantial percentage of patients will respond with long-term pain relief even to sham denervation,[159,160] it is unlikely that the routine use of confirmatory facet blocks will become standard of care anytime soon.

Treatment

Conservative Treatment and Pharmacotherapy

The treatment of l-z joint pain ideally consists of a multimodal approach comprising conservative therapy, medical management, procedural interventions, and if indicated, psychotherapy. There are no clinical studies specifically assessing pharmacotherapy or noninterventional treatment for lumbar facet arthropathy, although there are several controlled studies evaluating conservative treatment for axial LBP. Tailored exercise programs and yoga have been shown to reduce pain and prevent relapses in patients with chronic LBP.[186–190] In randomized, clinical trials, osteopathic manipulation has been shown to provide moderate relief for LBP patients,[191,192] although one study showed no difference between the benefits afforded by true and sham manipulation.[193] Acupuncture has also been shown in randomized trials to provide significant benefit in patients with chronic LBP.[194–196] However, similar to manipulation, one of the largest and most methodologically sound studies found no difference between true and sham acupuncture.[197]

Nonsteroidal antiinflammatory drugs and acetaminophen are widely considered first line drugs for the treatment of LBP, with little evidence to support one particular drug over another.[198–200] Adjuvants have also been shown to be effective in relieving LBP. In a comprehensive review on published clinical trials evaluating pharmacotherapy in LBP, Schnitzer *et al.*[201] found strong evidence to support the use of antidepressants for chronic LBP, and muscle relaxants in acute back pain. Numerous studies have also provided incontrovertible evidence that untreated psychopathology can adversely affect LBP treatment outcomes. In a study by Polatin *et al.*[202] conducted in 200 chronic LBP patients, the authors found that 77% met lifetime criteria and 59% demonstrated current symptoms for at least one psychiatric diagnosis, with the most common being depression, substance abuse, and anxiety disorders. Most, but not all studies, have shown untreated psychopathology to negatively impact LBP treatment outcomes.[203] In the only study assessing the influence of psychopathology on l-z joint interventions, Lilius *et al.*[204] found a strong correlation between a negative response to intraarticular and periarticular LA and steroid injections and inappropriate signs and symptoms. We believe that the optimal management of l-z joint pain should encompass both interventional and noninterventional treatment, although clinicians are encouraged to exercise caution when extrapolating the results of studies conducted in patients with nonspecific LBP to those with clear-cut facet pathology.

Intraarticular Steroid Injections

The use of intraarticular steroid injections to treat l-z joint pain is a controversial subject. In uncontrolled studies, the long-term relief of back pain after intraarticular steroid injection ranges from 18% to 63%, with most of these studies being conducted in patients who did not undergo previous diagnostic l-z blocks.[118–120,123,124,144,205] Studies have also reported intermediate-term pain relief after intraarticular LA alone,[142] normal saline,[206,207] and hyaluronic acid.[208]

In the controlled trials that do exist, the results are mixed (table 7). In the largest study, Lilius[207] reported no significant difference in outcomes between 109 patients who received large-volume (8 ml) LA and steroid injected into l-z joints or around l-z joints or intraarticular saline injections. In a randomized, controlled study comparing intraarticular steroid and saline in 97 patients

Copyright © by the American Society of Anesthesiologists. Unauthorized reproduction of this article is prohibited.
Downloaded from http://pubs.asahq.org/anesthesiology/article-pdf/106/3/591/363690/0000542-200703000-00024.pdf by guest on 23 September 2024

Table 7. Prospective, Clinical Trials Evaluating Intraarticular Steroid Injections for Lumbar Facet Joint Pain

Author, Year, Methodologic Score	Patients and Interventions	Results	Comments
Lynch and Taylor,[268] 1986; MQ score = 0	50 pts with chronic LBP accompanied by paraspinal tenderness and pain worsened by hyperextension underwent attempted intraarticular steroid injections at 2 most caudal l-z joints. Failed "extraarticular" injections designated as "control" group.	Relief of pain at 2 wk and 6 mo was better in pts who had 2 intraarticular injections than the other groups. Pts who had 1 intraarticular injection had better relief than those who had no successful injections.	Flaws include lack of randomization, poor outcome assessment, failure to identify pts based on diagnostic injections, and failure to blind the examining physician.
Lilius *et al.*,[207] 1989; MQ score = 1	109 pts with unilateral chronic LBP rec'd 8 ml LA and steroid injected into 2 l-z joints (n = 28), around 2 joints (n = 39), or 8 ml NS into 2 joints (n = 42).	All 3 groups demonstrated significant improvement in pain scores (at 3 mo), disability scores, clinical examination findings, and return to work at 6 wk after injection. No differences were noted on any variable between groups.	Pts were not diagnosed with l-z joint pain before injection. Large volumes used rendered injections nonspecific. Large SDs were found for variables measured. Other flaws include suboptimal outcomes measures and lack of a blinded observer. Pain scores measured at 3 mo by questionnaire.
Nash,[156] 1990; MQ score = 2	67 pts with chronic LBP were randomly assigned by pairs to receive either 1.5 ml intraarticular LA and steroid or MBB with 2 ml LA.	At 1-mo follow-up, 12 pairs reported MBB to be more beneficial, 11 reported intraarticular injection to be better, and 3 reported no difference.	11 pts lost to follow-up. Flaws include not using l-z joint blocks for diagnosis, lack of a blinded observer, poor outcome measures, and no true control group.
Carette *et al.*,[206] 1991; MQ score = 5	97 pts with chronic LBP who reported immediate relief after LA facet injections rec'd either 2 ml steroid and saline (n = 49) or saline (n = 48) into L4–L5 and L5–S1 l-z joints.	42% of pts who received steroid and 33% who rec'd placebo reported marked improvement for up to 3 mo (*P* = not significant). At 6 mo, the steroid group reported less pain and disability. Only 22% of pts in steroid group and 10% in placebo group had sustained improvement through 6 mo.	Differences between groups at 6 mo reduced when cointerventions taken into account. Although this is the only study that identified study pts based on diagnostic injections, these injections were not "controlled." NS is known to provide pain relief > that expected from placebo.
Marks *et al.*,[8] 1992; MQ score = 3	86 pts with chronic LBP were randomly assigned to receive either 1.5 ml steroid and LA MBB or intraarticular injections (2 ml at lowest level).	Pts who had facet joint injections had better pain relief than those who had MBB at all follow-up visits up to 3 mo, but this was only significant at 1-mo review.	Flaws include no true control group, failure to identify pts based on diagnostic injections, no monitoring of cointerventions, lack of a blinded observer, and poor outcome assessment.
Fuchs *et al.*,[208] 2005; MQ score = 1	60 pts with chronic LBP were randomly assigned to receive either 1 ml HA or steroid into the 3 lowest facet joints at weekly intervals × 6.	Pts who rec'd HA injections experienced a 40% decrease in pain scores *vs.* a 56% reduction in those who rec'd steroid (*P* = not significant). Greatest pain reduction observed 3 mo after treatment in HA group and 1 wk after treatment in steroid group.	Inclusion criteria included at least moderate facet degeneration on radiologic imaging. Flaws include lack of a control group, failure to identify pts based on diagnostic injections, no monitoring of cointerventions, and multiple injections.
Pneumaticos *et al.*,[215] 2006; MQ score = 3	47 pts with chronic LBP worse with lumbar extension and radiologic evidence of l-z joint abnormalities were randomly assigned in a 2:1 ratio to undergo intraarticular LA and steroid injections (3 ml) based on SPECT scans or physical examination.	1 mo after injection, 87% of pts with (+) SPECT had significant pain improvement *vs.* 12.5% of pts with (−) SPECT and 31% of pts who underwent injections based on physical examination.	Differences remained significant at 3 mo but not 6 mo after injection. Pain scores obtained by mailed questionnaire. No functional assessment done. Use of SPECT was cost effective.

Methodologic quality (MQ) score based on the 5-point Jadad scale.[275] A score of ≥ 3 indicates high methodologic quality.

HA = hyaluronic acid; LA = local anesthetic; LBP = low back pain; l-z = lumbar zygapophysial; MBB = medial branch block; NS = normal saline; pts = patients; SPECT = single photon emission computed tomography.

with chronic LBP, Carette *et al.* found a statistically significant benefit favoring steroid only at 6 months after the procedure.[206] This study is the second largest and most methodologically sound study evaluating intraarticular steroids, and the only one that prescreened study patients based on diagnostic facet blocks. One flaw in these studies is that most used saline injections as the control group, and normal saline has been shown to provide better pain relief than that expected with a true placebo for a multitude of invasive procedures.[209–211] In five recent review articles, the authors were split as to whether intraarticular steroids constituted an effective treatment for l-z joint pain, with three concluding they did not.[128,181,212–214] Based on the existing evidence, including basic science studies demonstrating inflammatory mediators to be present in and around degenerated facet joints,[43,44] we believe that intraarticular steroid injections may provide intermediate-term relief to a small subset of patients with l-z joint pain accompanied by an active inflammatory process. Evidence to support this assertion is bolstered by several recent prospective and observational studies evaluating low- to intermediate-volume (1–3 ml) LA and steroid intraarticular l-z joint injections performed in more than 160 patients with

Copyright © by the American Society of Anesthesiologists. Unauthorized reproduction of this article is prohibited.

Downloaded from http://pubs.asahq.org/anesthesiology/article-pdf/106/3/591/363690/0000542-200703000-00024.pdf by guest on 23 September 2024

axial LBP.[150,215,216] In these studies, patients with positive single photon emission computed tomography experienced dramatically better pain relief (> 75% success rate) compared with those with negative or no single photon emission computed tomography (< 40% success rate) up to 3 months after injection. In the two studies that followed patients for 6 months after injection, the beneficial effect wore off after the 3-month evaluation.[150,215] Radionuclide bone scintigraphy is capable of depicting synovial changes caused by inflammation, degenerative changes associated with bone remodeling, and increased metabolic function. In addition to radiologic evidence of joint inflammation and degeneration, intraarticular steroid injections may be more effective in those patients who obtain definitive pain relief after a diagnostic screening block, and when LA is added to the injectate.

Radiofrequency Denervation

In 1971, Rees[18] first described percutaneous denervation as an effective new treatment for discogenic back pain. Notwithstanding his greater than 99% reported success rate, it remains a subject of controversy as to whether his technique actually achieved "facet rhizolysis," since the instrument he used may not have been long enough to accomplish anything more than a myofasciotomy.[3] The technique as practiced today, which entails using radiofrequency energy channeled through a small-diameter needle to create a controlled burn that severs the l-z joint nerve supply, is generally credited to Shealy, who was motivated by what he perceived to be an unacceptably high incidence of local hemorrhagic complications.[19,20] Subsequently, it has been used with varying degrees of success to treat different forms of spinal pain, including whiplash,[217] sacroiliac joint pain,[218,219] discogenic pain,[220] and intractable sciatica.[221] There are literally dozens of uncontrolled trials touting the benefits of radiofrequency denervation for l-z joint pain,[222] with most reporting sustained relief in 50–80% of subjects without previous back surgery[19,223–228] and 35–50% of patients with failed back surgery syndrome.[153,229–232]

Only five placebo-controlled studies have been conducted evaluating radiofrequency denervation for l-z joint pain (table 8). In the first study, King and Lagger[3] randomly assigned 60 patients with low back and leg pain to receive empirical (without stimulation) radiofrequency denervation of the dorsal rami, a radiofrequency lesion made in the muscle, or a sham lesion after electrical stimulation. At their 6-month follow-up, 27% of patients in the facet denervation group experienced satisfactory pain relief *versus* 53% in the myotomy group and 0% in the sham group. The main criticism in this study is that no diagnostic blocks were performed to screen people for l-z joint pain. More than 15 yr later, Gallagher *et al.*[158] randomly assigned 41 patients based on their response to diagnostic intraarticular blocks (equivocal or good response) to either sham or true denervation. A statistically significant difference in outcomes was observed at 1 month only between sham and true radiofrequency denervation in those patients who obtained a definitive response to diagnostic blocks. This difference persisted for the duration of the 6-month follow-up. In the smallest but most methodologically sound[233] study among the five controlled trials, van Kleef *et al.*[157] found a 46% pain reduction in the radiofrequency lesion group *versus* an 8% reduction in the placebo group. At 12-month follow-up, 7 of 15 patients in the radiofrequency group continued to have a successful outcome *versus* only 2 of 16 in the sham group. Leclaire *et al.*[159] conducted a placebo-controlled study in 70 patients with a putative diagnosis of facet arthropathy. At their 4-week follow-up, the only outcome variable that favored the treatment group was an improvement in mean Roland-Morris disability score. At 12 weeks, no difference was noted between groups for pain levels or any measure of functional capacity. The key flaw in this study is that the authors used "significant pain relief lasting > 24 h" after an intraarticular injection of LA and steroid as their main inclusion criterion. In addition to being ambiguous, the 24-h threshold is inconsistent with the pharmacodynamics of lidocaine. In the largest controlled study evaluating radiofrequency denervation, van Wijk *et al.*[160] found the only difference between the treatment and control group at 3 months was that more radiofrequency patients reported a 50% or greater diminution in back pain than sham patients (62% *vs.* 39%). For mean reduction in VAS pain scores, change in analgesic intake, and functional assessments, no differences were noted between groups.

The chief criticisms of these studies (see table 8 for more details) include suboptimal needle positioning and not selecting study patients based on placebo-controlled or comparative LA blocks. In the only prospective study to evaluate radiofrequency outcomes in patients selected based on concordant response to serial LA blocks, Dreyfuss *et al.*[182] reported that 87% of 15 patients obtained at least 60% pain relief 12 months status post radiofrequency denervation, with 60% of patients achieving at least 90% relief. In addition to stringent inclusion criteria, the authors used 16-gauge electrodes and assessed the efficacy of radiofrequency denervation by performing electromyography of the multifidus muscles.

Whereas some may construe these findings as evidence that radiofrequency denervation is a fundamentally flawed treatment, a more plausible interpretation is that they indicate a strong need to optimize radiofrequency denervation techniques and better identify those candidates who are likely to obtain positive outcomes. Several investigators have determined that placing the electrode parallel rather than perpendicular to the target nerve substantially increases the size of the lesion,

Copyright © by the American Society of Anesthesiologists. Unauthorized reproduction of this article is prohibited.
Downloaded from http://pubs.asahq.org/anesthesiology/article-pdf/106/3/591/363690/0000542-200703000-00024.pdf by guest on 23 September 2024

Table 8. Outcomes for Randomized, Controlled Studies Assessing Medial Branch Radiofrequency Denervation for Facet Joint Pain

Author, Year	Number and Type of Patients	Follow-up Period and Methodologic Scores	Results	Comments
King and Lagger,[3] 1976	60 pts with chronic low back and leg pain and paraspinal tenderness were randomly assigned to 3 groups. Group I had RF denervation of the primary posterior ramus, group II had RF performed using a 1.25-inch needle inserted within the area of maximum tenderness (assumed to be a myotomy), and group III rec'd stimulation but no coagulation (control).	6 mo; MQ = 2; CR = 5	In group I, 27% had ≥ 50% relief at 6 mo vs. 53% in group II and 0% in group III.	Did not use diagnostic blocks before randomization. Likely included many pts with sciatica. In some pts, 1.25 inches may be sufficient to reach the medial branch. Used 120-s lesion; 3 lesions were empirically made without electrical stimulation. Electrode not placed parallel to nerve.
Gallagher *et al.*,[158] 1994	Subjects were 41 pts with chronic LBP who obtained "clear-cut or equivocal" relief from single intraarticular facet joint injections with LA and steroid. 18 pts with a good response and 6 pts with an equivocal response underwent RF denervation. 12 pts with a good response and 5 with an equivocal response underwent sham denervation.	6 mo; MQ = 2; CR = 6	Significant differences in pain scores noted only between patients with a good response to LA blocks who underwent true RF denervation (n = 18) and those with a good response who underwent sham treatment (n = 12). Differences were noted 1 and 6 mo after procedures.	Did not define "good" or "equivocal" response to diagnostic injections. Anatomical landmarks not well described. Observer not blinded. Electrode not placed parallel to nerve. In Methods, stated only LA used, but in abstract, stated LA and steroid were used. Used 90-s lesions.
van Kleef *et al.*,[157] 1999	Subjects were 31 pts with chronic LBP who obtained ≥ 50% pain relief after a single MBB (1 dropout). Compared true denervation with sham.	12 mo; MQ = 5; CR = 8	After 3 mo, 9 of 15 pts in lesion group *vs.* 4 of 16 in sham group had ≥ 50% pain relief. At 1-yr follow-up, 7 of 15 in lesion group and 2 of 16 in sham group had ≥ 50% relief.	Used 0.75 ml injectate for diagnostic blocks. Electrode not placed perpendicular to target nerve. Used multifidus rather than sensory stimulation to identify medial branch. Used 60-s lesions.
Sanders and Zuurmond,[276] 1999	Subjects were 34 pts with chronic LBP who obtained ≥ 50% after single intraarticular injection with lidocaine. Half of the pts rec'd medial branch RF denervation, and half rec'd intraarticular denervation.	3 mo; MQ = 1; CR = 6	Both groups improved at 3 mo, but intraarticular denervation group improved more than medial branch RF group.	Used 1 ml for diagnostic blocks. Medial branch lesions done at inferolateral aspect of facet capsule and upper border of transverse process. 3 intraarticular facet lesions done. Used 60-s lesions.
Leclaire *et al.*,[159] 2001	Subjects were 70 pts with chronic LBP who obtained "significant" pain relief lasting > 24 h after single intraarticular facet injection with lidocaine and steroid (4 dropouts). Compared true denervation with sham.	12 wk; MQ = 4; CR = 8	At 4 wk, there were modest improvements in Roland-Morris (P = 0.05) and VAS pain scores (P = not significant), but not Oswestry score. No difference in any outcome measure at 12 wk.	Did not define "significant pain relief" with diagnostic injection. Inclusion criteria of > 24 h pain relief is inconsistent with pharmacology of lidocaine. Performed 2 lesions, each for 90 s. Anatomical landmarks not noted. Electrode not placed parallel to nerve.
van Wijk *et al.*,[160] 2005	81 pts with chronic LBP who obtained ≥ 50% pain relief after 2-level intraarticular facet injection with LA (no dropouts). Compared true denervation with sham.	12 mo; MQ = 5; CR = 7	Combined outcome measure (pain score, physical activity, and analgesic intake) showed no differences between groups at 3 mo. VAS pain score improved in both groups at 3 mo. Global perceived effect was greater in treatment than sham group at 3 mo.	Blinding ended at 3 mo in > 70% of pts. Improvement in pain scores persisted throughout 12-mo follow-up. Used 60-s lesions.

Methodologic quality (MQ) score based on the 5-point Jadad scale.[275] A score of ≥ 3 indicates high methodologic quality. Clinical relevance (CR) score based on patient selection parameters and radiofrequency (RF) technique description (0–9 scale) as described by Geurts *et al.*[233]

LA = local anesthetic; LBP = low back pain; MBB = medial branch block; pts = patients; rec'd = received; VAS = visual analog scale.

thereby reducing the likelihood the treatment will miss or only partially coagulate the target nerve.[234,235] After a literature review and cadaveric study, Lau *et al.*[234] concluded the ideal electrode position is across the lateral neck of the superior articular process rather than the groove formed at the angle of the superior articular and transverse processes, as was used in most studies.[159,160] Other investigators have found the maximal lesion size to be reached within 60 s of lesion time,[235–237] independent of whether the system is temperature or voltage-controlled.[238] Studies conducted in human myocardium have determined that irrigation fluid has either no effect or a slightly beneficial effect on lesion size.[239] Hence, the use of LA to prevent procedure-related pain or steroid to reduce the incidence of neuritis[184] should theoretically have no adverse effects on the efficacy of radiofrequency denervation.

Another flaw that pervades most radiofrequency stud-

Copyright © by the American Society of Anesthesiologists. Unauthorized reproduction of this article is prohibited.

Downloaded from http://pubs.asahq.org/anesthesiology/article-pdf/106/3/591/363690/0000542-200703000-00024.pdf by guest on 23 September 2024

ies is that sensory stimulation (usually at ≤ 0.5 V) is used to corroborate proximity of the electrode to the targeted medial branch. Whereas sensory stimulation is almost certain to be perceived when the electrode is placed on or adjacent to a neural structure, it is our experience that many patients perceive concordant sensory stimulation at 0.5 V or less, even when the electrode is purposefully placed in muscle, as during sham procedures. An attractive alternative to sensory stimulation is to instead (or in addition) attempt to elicit multifidus muscle contraction, because the same medial branch that innervates the facet joint also innervates this paraspinal muscle. In the two studies in which the medial branch was identified by motor stimulation of the multifidus muscle, both reported positive outcomes.[157,182]

In a large, multicenter outcome study, Cohen *et al.*[153] attempted to identify factors associated with successful radiofrequency treatment in 192 patients who underwent denervation at three teaching hospitals after a single, positive MBB. Among the 15 variables analyzed for their association with treatment outcome, only paraspinal tenderness was found to predict a successful treatment. Factors associated with failed treatment included increased pain with hyperextension and axial rotation (*i.e.*, facet loading), duration of pain and previous back surgery. The latter two variables have been associated with treatment failure not only for radiofrequency denervation, but a host of other LBP interventions as well, including epidural steroid injections and open surgery.[240–242] When pain returns after radiofrequency denervation, which typically occurs between 6 months and 1 yr, repeated neurotomy can be performed with no diminution in efficacy.[243] In addition to continuous, high-temperature radiofrequency medial branch ablation, pulsed radiofrequency (2–6 months of effective pain relief),[244] cryodenervation (3–6 months of pain relief),[245–248] and phenol neurolysis[249,250] have also been reported to provide intermediate to long-term pain relief in uncontrolled studies.

Complications after Intraarticular Injections and Radiofrequency Denervation

Serious complications and side effects are extremely uncommon after facet interventions. The metabolic and endocrine sequelae of intrafacetal depot steroids have not been studied, but extrapolating from epidural steroid injections, one would expect suppression of the hypothalamic–pituitary–adrenal axis lasting up to 4 weeks depending on the depot steroid used, and impaired insulin sensitivity manifesting as elevated glucose levels for less than a week.[251,252] Although rare, a host of infections have been reported after intraarticular injections including septic arthritis, epidural abscess, and meningitis.[253–255] Case reports of spinal anesthesia and postdural puncture headache have also been published.[256,257]

Numbness and/or dysesthesias have been reported after radiofrequency denervation but tend to be transient and self-limiting.[219,258] Burns are rare with radiofrequency procedures and may result from electrical faults, insulation breaks in the electrodes, and generator malfunction.[19,226,259] The most common complication after facet joint radiofrequency is neuritis, with a reported incidence of less than 5%.[183] In one study, the administration of corticosteroid or pentoxifylline was found to reduce the incidence of postprocedure pain after radiofrequency denervation.[184] There is also a theoretical risk of thermal injury to the ventral rami if an electrode slips ventrally over the transverse process.

Surgery

Surgery is occasionally performed to treat facet arthropathy despite a lack of evidence supporting fusion for degenerative spinal disorders.[260,261] Not surprisingly, the results of studies evaluating the use of l-z joint blocks to predict lumbar arthrodesis outcomes are discouraging (table 9). In the three studies that compared surgical outcomes between facet block responders and nonresponders, all three failed to show a difference between groups.[262–264] Bough *et al.*[138] conducted a retrospective review of 127 facet joints surgically removed from 84 patients in an attempt to correlate histologic evidence of facet degeneration with provocative response to preoperative facet arthrography. Although the authors found the positive predictive value of concordant pain reproduction to be 85%, the negative predictive value was only 43%, leading them to conclude that provocative facet arthrography was of little value as a presurgical screening tool. In a prospective case series, Lovely and Rastogi[265] found that 83% of 23 patients who responded to bracing and three successive facet blocks achieved at least 90% pain relief after fusion surgery at the latest follow-up. However, the large volumes used per block, the failure to exclude placebo-responders, and the lack of any comparison group undermine the conclusions that can be drawn. One reason patients with l-z joint pain might respond to arthrodesis is because some surgeons, either purposefully or inadvertently, perform medial branch rhizotomies during pedicle screw placement. In summary, there is no convincing evidence to support any surgical intervention for l-z joint pain aside from that resulting from a traumatic dislocation.

Conclusions

Pain originating from the l-z joints has long been recognized as a potential source of LBP. Anatomical studies suggest that with aging, the facet joints become weaker and their orientation changes from coronal to sagittal

Downloaded from http://pubs.asahq.org/anesthesiology/article-pdf/106/3/591/363690/0000542-200703000-00024.pdf by guest on 23 September 2024

Copyright © by the American Society of Anesthesiologists. Unauthorized reproduction of this article is prohibited.

Table 9. Studies Evaluating the Ability of Lumbar Facet Blocks to Predict Operative Results

Author, Year	Patients and Methods	Results	Comments
Esses *et al.*,[263] 1989	Prospective study evaluating the value of external fixation to predictive fusion outcome in 35 pts. 14 pts underwent preoperative facet blocks.	Among the 9 pts who reported temporary relief from facet blocks, 5 experienced relief from external fixation. In the 5 pts who had no relief with facet blocks, 4 experienced relief after fixation.	Study not designed to assess value of facet blocks in predicting outcome of spinal fixation.
Bough *et al.*,[138] 1990	Retrospective study comparing results of surgical pathology and preoperative provocative facet arthrography in 84 pts who underwent spinal fusion.	The specificity of pain provocation for facet disease was 75%, sensitivity 59%, positive predictive value 85%, and negative predictive value 43%. The authors concluded symptom provocation during facet arthrography was of little value as a surgical screening tool.	Histopathology results reviewed for 127 l-z joints. Clinical outcomes not discussed.
Jackson,[262] 1992	Retrospective review involving 36 pts who underwent posterolateral lumbar fusion after facet injections.	Both groups improved after fusion. The 26 pts who responded favorably to facet injections did no better clinically than the 10 pts who did not.	Mean follow-up 6.1 yr. Response to injection not a consideration for fusion.
Esses and Moro,[264] 1993	Retrospective review involving the results of spinal fusion (n = 82) and nonoperative treatment (n = 44) in 126 pts who underwent facet blocks.	15% of pts had complete relief, 41% partial relief, and 44% no relief after l-z joint blocks. Response to facet blocks not predictive of surgical or nonsurgical success.	296 pts underwent facet blocks during index period, but only 126 had follow-up (mean 4.6 yr.
Lovely and Rastogi,[265] 1997	Prospective case series involving 91 pts who responded to bracing and underwent 197 facet blocks. 28 pts who obtained > 70% pain relief on 3 separate occasions underwent spinal fusion.	Fusion was technically successful 77% of time. 83% of pts reported ≥ 90% relief, and 13% reported partial relief.	Mean follow-up 32 mo. No comparison group who either failed or did not receive preoperative l-z joint blocks. Used 3–5 ml injectate per facet level.

l-z = lumbar zygapophysial; pts = patients.

positioning, predisposing them to injury from rotational stress. The three most caudal facet joints, L3–L4, L4–L5, and L5–S1, are exposed to the greatest strain during lateral bending and forward flexion and are thus more prone to repetitive strain, inflammation, joint hypertrophy, and osteophyte formation. Osteoarthritis of the facet joints is commonly found in association with degenerative disc disease. The exact prevalence of facet disease resulting in axial LBP is unclear but may be as high as 10–15% of patients.

There are no discrete historic and physical findings pathognomonic for lumbar facet arthropathy. The referral patterns for pain arising from the lumbar facet joints at different levels overlap considerably. In addition to axial LBP, pathology arising from the lower facet joints is associated with referred pain to the buttock, thigh, groin, and sometimes lower leg, whereas that referred from the upper lumbar facet joints extends into the flank, hip, groin, and lateral thigh. Reports on the correlation between CT and MRI evidence of facet arthropathy and the response to diagnostic lumbar facet blocks are conflicting. Because the facet joint is innervated by the medial branches arising from the posterior rami of the spinal nerve at the same level and a level above the joint, LA blocks of these nerves have been advocated for diagnostic and prognostic purposes. Intraarticular l-z joint injection with LA has also been proposed as a method for diagnosing facet joint pain, with both procedures appearing to provide comparable diagnostic value. As with other blocks, the potential for false positive and false negative responses must be considered, and steps should taken to reduce their incidence.

In addition to providing short and occasionally intermediate-term pain relief, diagnostic blocks are considered predictive of the potential usefulness of subsequent neurolytic procedures such as radiofrequency denervation. In carefully selected patients who fail conservative treatments such as physical and pharmacologic therapies, intraarticular steroid injections and radiofrequency denervation are treatment options. Studies evaluating the long-term outcomes from these procedures have

Copyright © by the American Society of Anesthesiologists. Unauthorized reproduction of this article is prohibited.
Downloaded from http://pubs.asahq.org/anesthesiology/article-pdf/106/3/591/363690/0000542-200703000-00024.pdf by guest on 23 September 2024

thus far provided conflicting evidence. The results of surgical therapies including arthrodesis for facet arthropathy are discouraging.

The authors thank Paul Dreyfuss, M.D. (Professor of Physical Medicine and Rehabilitation, University of Washington School of Medicine, Seattle, Washington), for his review of the manuscript.

References

1. Manchikanti L: The growth of interventional pain management in the new millennium: A critical analysis of utilization in the Medicare population. Pain Physician 2004; 7:465–82
2. Lewin T, Moffett B, Vidik A: The morphology of the lumbar synovial intervertebral joints. Acta Morphol Neerl Scand 1962; 4:299–319
3. King JS, Lagger R: Sciatica viewed as a referred pain syndrome. Surg Neurol 1976; 5:46–50
4. Borenstein D: Does osteoarthritis of the lumbar spine cause chronic low back pain? Curr Pain Headache Rep 2004; 8:512–7
5. Cavanaugh JM, Ozaktay AC, Yamashita HT, King AI: Lumbar facet pain: Biomechanics, neuroanatomy and neurophysiology. J Biomechanics 1996; 29: 1117–29
6. Stillwell DL: The nerve supply of the vertebral column and its associated structures in the monkey. Anat Rec 1956; 125:136–69
7. Hirsch C, Ingelmark BE, Miller M: The anatomical basis for low back pain: Studies on the presence of sensory nerve endings in ligamentous, capsular and intervertebral disc structures in the human lumbar spine. Acta Orthop Scand 1963; 33:1–17
8. Marks RC, Houston T, Thulbourne T: Facet joint injection and facet nerve block: A randomized comparison in 86 patients with chronic low back pain. Pain 1992; 49:325–8
9. Mooney V, Robertson J: The facet syndrome. Clin Orthop Relat Res 1976; 115:149–56
10. McCall IW, Park WM, O'Brien JP: Induced pain referral from posterior lumbar elements in normal subjects. Spine 1979; 4:441–6
11. Kuslich SD, Ulstrom CL, Michael CJ: The tissue origin of low back pain and sciatica: A report of pain response to tissue stimulation during operations on the lumbar spine using local anesthesia. Orthop Clin North Am 1991; 22:181–7
12. Schwarzer AC, Aprill CN, Derby R, Fortin J, Kine G, Bogduk N: Clinical features of patients with pain stemming from the lumbar zygapophysial joints: Is the lumbar facet syndrome a clinical entity? Spine 1994; 19:1132–7
13. Goldthwaite JE: The lumbosacral articulation: An explanation of many cases of lumbago, sciatica, and paraplegia. Boston Med Surg J 1911; 164:365–72
14. Putti V: New concepts in the pathogenesis of sciatica pain. Lancet 1927; 2:53–60
15. Ghormley RK: Low back pain with special reference to the articular facets, with presentation of an operative procedure. JAMA 1933; 101:1773–7
16. Mixter WJ, Barr JS: Rupture of the intervertebral disc with involvement of the spinal canal. N Engl J Med 1934; 211:210–5
17. Badgley CE: The articular facets in relation to low back pain and sciatic radiation. J Bone Joint Surg (Am) 1941; 23:481–96
18. Rees WE: Multiple bilateral subcutaneous rhizolysis of segmental nerves in the treatment of the intervertebral disc syndrome. Ann Gen Pract 1971; 26:126–7
19. Shealy CN: Percutaneous radiofrequency denervation of spinal facets: Treatment for chronic back pain and sciatica. J Neurosurg 1975; 43:448–51
20. Shealy CN: Facet denervation in the management of back and sciatic pain. Clin Orthop 1976; 115:157–64
21. Glover JR: Arthrography of the joints of the lumbar vertebral arches. Orthop Clin North Am 1977; 8:37–42
22. Yahia LH, Garzon S: Structure on the capsular ligaments of the facet joints. Ann Anat 1993; 175:185–8
23. Cyron BM, Hutton WC: The tensile strength of the capsular ligaments of the apophyseal joints. J Anat 1981; 132:145–50
24. Bogduk N: Clinical Anatomy of the Lumbar Spine and Sacrum, 3rd edition. Edinburgh, Churchill Livingstone, 1997, pp 33–42
25. Pedersen HE, Blunck CF, Gardner E: The anatomy of the lumbosacral posterior rami and meningeal branches of spinal nerves (sinuvertebral nerves)—with an experimental study of their function. J Bone Joint Surg (Am) 1956; 38:377–91
26. Bogduk N: Clinical Anatomy of the Lumbar Spine and Sacrum, 3rd edition. Edinburgh, Churchill Livingstone, 1997, pp 127–44
27. Maigne JY, Maigne R, Guerin-Surville H: The lumbar mamillo-accessory foramen: A study of 203 lumbosacral spines. Surg Radiol Anat 1991; 13:29–32
28. Bogduk N, Tynan W, Wilson AS: The nerve supply to the human lumbar intervertebral discs. J Anat 1981; 132:39–56
29. Bogduk N, Wilson AS, Tynan W: The human lumbar dorsal rami. J Anat 1982; 134:383–97
30. Bogduk N: The innervation of the lumbar spine. Spine 1983; 8:286–93
31. Dreyfuss P, Schwarzer AC, Lau P, Bogduk N: Specificity of lumbar medial branch and L5 dorsal ramus blocks: A computed tomography study. Spine 1997; 22:895–902
32. Kaplan M, Dreyfuss P, Halbrook B, Bogduk N: The ability of lumbar medial branch blocks to anesthetize the zygapophysial joint: A physiologic challenge. Spine 1998; 23:1847–52
33. Paris SV: Anatomy as related to function and pain. Orthop Clin North Am 1983; 14:475–89
34. Jerosch J, Castro WH, Liljenqvist U: Percutaneous facet coagulation: Indication, technique, results, and complications. Neurosurg Clin North Am 1996; 7:119–34
35. Emminger E: Les articulations interapophysaires et leurs structures meniscoides vue sous l'angle de la pathologie. Ann Med Physique 1972; 15:219–38
36. Pedersen HE, Blunck CF, Gardner E: The anatomy of lumbosacral posterior rami and meningeal branches of spinal nerves (sinuvertebral nerves). J Bone Joint Surg (Am) 1956; 38:377–91
37. Suseki K, Takahashi Y, Takahashi K, Chiba T, Tanaka K, Morinaga T, Nakamura S, Moriya H: Innervation of the lumbar facet joints: Origins and functions. Spine 1997; 22:477–85
38. Ashton IK, Ashton BA, Gibson SJ, Polak JM, Jaffray DC, Eisenstein SM: Morphological basis for back pain: The demonstration of nerve fibers and neuropeptides in the lumbar facet joint capsule but not in ligamentum flavum. J Orthop Res 1992; 10:72–8
39. El-Bohy AA, Cavanaugh JM, Getchell ML, Bulas T, Getchell TV, King AI: Localization of substance P and neurofilament immunoreactive fibers in the lumbar facet joint capsule and supraspinous ligament of the rabbit. Brain Res 1988; 460:379–82
40. Beaman DN, Graziano GP, Glover RA, Wojtys EW, Chang V: Substance P innervation of lumbar spine facet joints. Spine 1993; 18:1044–9
41. Giles LG: Human lumbar zygapophyseal joint inferior recess synovial folds: A light microscope examination. Anat Rec 1988; 220:117–24
42. Giles LG, Taylor JR: Innervation of lumbar zygapophyseal joint synovial folds. Acta Orthop Scand 1987; 58:43–6
43. Willburger RA, Wittenberg RH: Prostaglandin release from lumbar disc and facet joint tissue. Spine 1994; 19:2068–70
44. Igarashi A, Kikuchi S, Konno S, Olmarker K: Inflammatory cytokines released from the facet joint tissue in degenerative lumbar spinal disorders. Spine 2004; 29:2091–5
45. Horwitz T, Smith RM: An anatomical, pathological and roentgenological study of the intervertebral joints of the lumbar spine and of the sacroiliac joints. Am J Roentgenol 1940; 43:173–86
46. Masharawi Y, Rothschild B, Dar G, Peleg S, Robinson D, Been E, Hershkovitz I: Facet orientation in the thoracolumbar spine: Three-dimensional anatomic and biomechanical analysis. Spine 2004; 29:1755–63
47. Panjabi MM, Oxland T, Takata K, Goel V, Duranceau J, Krag M: Articular facets of the human spine: Quantitative three-dimensional anatomy. Spine 1993; 18:1298–1310
48. Grobler LJ, Robertson PA, Novotny JE, Pope MH: Etiology of spondylolisthesis: Assessment of the role played by lumbar facet joint morphology. Spine 1993; 18:80–91
49. Boden SD, Riew KD, Yamaguchi K, Branch TP, Schellinger S, Wiesel SW: Orientation of the lumbar facet joints: Association with degenerative disc disease. J Bone Joint Surg (Am) 1996; 78:403–11
50. Murtagh FR, Paulsen RD, Rechtine GR: The role and incidence of facet tropism in lumbar spine degenerative disc disease. J Spinal Disord 1991; 4:86–9
51. Dai LY: Orientation and tropism of lumbar facet joints in degenerative spondylolisthesis. Int Orthop 2001; 25:40–2
52. Farfan HF, Huberdeau RM, Dubow HI: Lumbar intervertebral disc degeneration: The influence of geometric features on the pattern of disc degeneration—a post-mortem study. J Bone Joint Surg (Am) 1972; 54:492–510
53. Cyron BM, Hutton WC: Articular tropism and stability of the lumbar spine. Spine 1980; 5:168–72
54. Noren R, Trafimow J, Andersson GB, Huckman MS: The role of facet joint tropism and facet angle in disc degeneration. Spine 1991; 16:530–2
55. Van Schaik JP, Verbiest H, Van Schaik FD: The orientation of laminae and facet joints in the lower lumbar spine. Spine 1985; 10:59–63
56. Vanharanta H, Floyd T, Ohnmeiss DD, Hochschuler SH, Guyer RD: The relationship of facet tropism to degenerative disc disease. Spine 1993; 18:1000–5
57. Yang KH, King AI: Mechanism of facet load transmission as a hypothesis for low-back pain. Spine 1984; 9:557–65
58. Adams MA, Hutton WC: The effect of posture on the role of the apophysial joints in resisting intervertebral compressive forces. J Bone Joint Surg (Br) 1980; 62:358–62
59. Nachemson AL: The load on lumbar discs in different positions of the body. Clin Orthop 1966; 45:107–22
60. Lorenz M, Patwardhan A, Vanderby R Jr: Load-bearing characteristics of lumbar facets in normal and surgically altered spinal segments. Spine 1983; 8:122–30
61. Song KJ, Lee KB: Bilateral facet dislocation on L4-5 without neurologic deficit. J Spinal Disord 2005; 18:462–4
62. Ianuzzi A, Little JS, Chiu JB, Baitner A, Kawchuk G, Khalsa PS: Human lumbar facet joint capsule strains: I. During physiological motions. Spine J 2004; 4:141–52
63. Little JS, Ianuzzi A, Chiu JB, Baitner A, Khalsa PS: Human lumbar facet joint

Downloaded from http://pubs.asahq.org/anesthesiology/article-pdf/106/3/591/363690/0000542-200703000-00024.pdf by guest on 23 September 2024

Copyright © by the American Society of Anesthesiologists. Unauthorized reproduction of this article is prohibited.

capsule strains: II. Alteration of strains subsequent to anterior interbody fixation. Spine J 2004; 4:153–62
64. Esses SI, Doherty BJ, Crawford MJ, Dreyzin V: Kinematic evaluation of lumbar fusion techniques. Spine 1996; 21:676–84
65. Chow DH, Luk LD, Evans JH, Leong JC: Effects of short anterior lumbar interbody fusion on biomechanics of neighboring unfused segments. Spine 1996; 21:549–55
66. Lee CK: Accelerated degeneration of the segment adjacent to a lumbar fusion. Spine 1988; 13:375–7
67. Lee CK, Langrana NA: Lumbosacral spinal fusion: A biomechanical study. Spine 1984; 9:574–81
68. Quinnell RC, Stockdale HR: Some experimental observations of the influence of a single lumbar floating fusion on the remaining spine. Spine 1981; 6:263–7
69. Little JS, Khalsa PS: Human lumbar spine creep during cyclic and static flexion: Creep rate, biomechanics, and facet joint capsule strain. Ann Biomed Eng 2005; 33:391–401
70. Little JS, Khalsa PS: Material properties of the human lumbar facet joint capsule. J Biomech Eng 2005; 127:15–24
71. Dory MA: Arthrography of the lumbar facet joints. Radiology 1981; 140: 23–7
72. Gray DP, Bajwa ZH, Warfield CA: Facet block and neurolysis, Interventional Pain Management, 2nd edition. Edited by Waldman SD. Philadelphia, WB Saunders, 2001, pp 446–83
73. Oudenhoven RC: Lumbar monoradiculopathy due to unilateral facet hypertrophy. Neurosurgery 1982; 11:726–7
74. Wilde GP, Szypryt ET, Mulholland RC: Unilateral lumbar facet joint hypertrophy causing nerve root irritation. Ann R Coll Surg Engl 1988; 70:307–10
75. Pape E, Eldevik P, Vandvik B: Diagnostic validity of somatosensory evoked potentials in subgroups of patients with sciatica. Eur Spine J 2002; 11:38–46
76. Kang YM, Choi WS, Pickar JG: Electrophysiologic evidence for an intersegmental reflex pathway between lumbar paraspinal tissues. Spine 2002; 27: E56–63
77. Indahl A, Kaigle A, Reikeras O, Holm S: Electromyographic response of the porcine multifidus musculature after nerve stimulation. Spine 1995; 20:2652–8
78. Yamashita T, Cavanaugh JM, El-Bohy AA, Getchell TV, King AI: Mechanosensitive afferent units in the lumbar facet joint. J Bone Joint Surg (Am) 1990; 72:865–70
79. Yamashita T, Minaki Y, Seiichi I, Cavanaugh JM, King AI: Somatosensory innervation of the lumbar spine and adjacent tissues. Trends Comparat Biochem Physiol 1993; 1:219–27
80. Aramov AI, Cavanaugh JM, Ozaktay AC, Getchell TV, King AI: Effects of controlled mechanical loading on group III and IV afferents from the lumbar facet joint: An *in vitro* study. J Bone Joint Surg (Am) 1992; 74:1464–71
81. Ozaktay AC, Cavanaugh JM, Blagoev D, Getchell TV, King AI: Effects of carrageenan induced inflammation in rabbit lumbar facet joint capsule and adjacent tissue. Neurosci Res 1994; 20:355–64
82. Ozaktay AC, Kallakuri S, Cavanaugh JM, King AI: Phospholipase A_2 induced electrophysiologic and histologic changes in rabbit dorsal lumbar spine tissue. Spine 1995; 20:2659–68
83. Yamashita T, Cavanaugh JM, Ozaktay AC, Avramov AI, Getchell TV, King AI: Effect of substance P on mechanosensitive units of tissues around and in the lumbar facet joint. J Orthop Res 1993; 11:205–14
84. Cavanaugh JM, Ozaktay C, Yamashita T, Aramov A, Getchell TV, King AI: Mechanisms of low back pain: A neurophysiologic and neuroanatomic study. Clin Orthop Relat Res 1997; 335:166–80
85. Woolf CJ, Salter MW: Neuronal plasticity: Increasing the gain in pain. Science 2000; 288:1765–9
86. Boszczyk BM, Boszczyk AA, Putz R: Comparative and functional anatomy of the mammalian lumbar spine. Anat Rec 2001; 264:157–68
87. Revel ME, Listrat VM, Chevalier XJ, Dougados M, Nguyen MP, Vallee C, Wybier M, Gires F, Amor B: Facet joint block for low back pain: Identifying predictors of a good response. Arch Phys Med Rehabil 1992; 73:824–8
88. Revel M, Poiraudeau S, Auleley GR, Payan C, Denke A, Nguyen M, Chevrot A, Fermanian J: Capacity of the clinical picture to characterize low back pain relieved by facet joint anesthesia: Proposed criteria to identify patients with painful facet joints. Spine 1998; 23:1972–6
89. Jackson RP, Jacobs RR, Montesano PX: Facet joint injection in low-back pain: A prospective statistical study. Spine 1988; 13:966–71
90. Kirkaldy-Willis WH, Farfan FH: Instability of the lumbar spine. Clin Orthop 1982; 165:110–23
91. Farfan HF: Effects of torsion on the intervertebral joints. Can J Surg 1969; 12:336–41
92. Kirkaldy-Willis WH, Wedge JH, Yong-Hing K, Reilly J: Pathology and pathogenesis of lumbar spondylosis and stenosis. Spine 1978; 3:319–28
93. Gottfried Y, Bradford DS, Oegema TR: Facet joint changes after chemonucleolysis induced disc space narrowing. Spine 1986; 11:944–54
94. Panjabi MM, Krag MH, Chung TQ: Effects of disc injury on mechanical behavior of the human spine. Spine 1984; 9:707–13
95. Haher TR, O'Brien M, Dryer JW, Nucci R, Zipnick R, Leone DJ: The role of the lumbar facet joints in spinal stability. Spine 1994; 19:2667–71
96. Adams MA, Freeman BJ, Morrison HP, Nelson IW, Dolan P: Mechanical initiation of intervertebral disc degeneration. Spine 2000; 25:1625–36
97. Fujiwara A, Tamai K, Yamato M, An HS, Yoshida H, Saotome K, Kurihashi A: The relationship between facet joint osteoarthritis and disc degeneration of the lumbar spine: An MRI study. Eur Spine J 1999; 8:396–401
98. Schwarzer AC, Aprill CN, Derby R, Fortin J, Kine G, Bogduk N: The relative contributions of the disc and zygapophyseal joint in chronic low back pain. Spine 1994; 19:801–6
99. de Vlam K, Mielants H, Verstaete KL, Veys EM: The zygapophyseal joint determines morphology of the enthesophyte. J Rheumatol 2000; 27:1732–9
100. Guillaume MP, Hermanus N, Peretz A: Unusual localisation of chronic arthropathy in lumbar facet joints after parvovirus B19 infection. Clin Rheumatol 2002; 21:306–8
101. Ball J: Enthesopathy of rheumatoid and ankylosing spondylitis. Ann Rheum Dis 1971; 30:213–23
102. Campbell AJ, Wells IP: Pigmented villonodular synovitis of a lumbar vertebral facet joint. J Bone Joint Surg (Am) 1982; 64:145–6
103. Smida M, Lejri M, Kandara H, Sayed M, Ben Chehida F, Ben Ghachem M: Septic arthritis of a lumbar facet joint case report and review of the literature. Acta Orthop Belg 2004; 70:290–4
104. Eisenstein SM, Parry CR: The lumbar facet arthrosis syndrome. J Bone Joint Surg (Br) 1987; 69:3–7
105. Dreyfuss PH, Dreyer SJ, Herring SA: Lumbar zygapophysial (facet) joint injections. Spine 1995; 20:2040–7
106. Fujishiro T, Nabeshima Y, Yasui S, Fujita I, Yoshiya S, Fujii H: Pseudogout attack of the lumbar facet joint: A case report. Spine 2002; 27:E396–8
107. Hemminghytt S, Daniels DL, Williams AL, Haughton VM: Intraspinal synovial cysts: Natural history and diagnosis by CT. Radiology 1982; 145:375–6
108. Howington JU, Connolly ES, Voorhies RM: Intraspinal synovial cysts: 10-year experience at the Ochsner Clinic. J Neurosurg 1999; 91 (suppl):193–9
109. Sabo RA, Tracy PT, Weinger JM: A series of 60 juxtafacet cysts: Clinical presentation, the role of spinal instability, and treatment. J Neurosurg 1996; 85:860–5
110. Rapin PA, Gerster JC: Calcified synovial cysts of zygapophyseal joints. J Rheumatol 1993; 20:767–8
111. Doyle AJ, Merrilees M: Synovial cysts of the lumbar facet joints in a symptomatic population: Prevalence on magnetic resonance imaging. Spine 2004; 29:874–8
112. Das De S, McCreath SW: Lumbosacral fracture dislocations: A report of four cases. J Bone Joint Surg (Br) 1981; 63:58–60
113. Fabris D, Costantini S, Nena U, Lo Scalzo V: Traumatic L5-S1 spondylolisthesis: Report of three cases and a review of the literature. Eur Spine J 1999; 8:290–5
114. Kaplan SS, Wright NM, Yundt KD, Lauryssen C: Adjacent fracture-dislocations of the lumbosacral spine: Case report. Neurosurgery 1999; 44:1134–7
115. Verlaan JJ, Oner FC, Dhert WJ, Verbout AJ: Traumatic lumbosacral dislocation: Case report. Spine 2001; 26:1942–4
116. Veras del Monte LM, Bago J: Traumatic lumbosacral dislocation. Spine 2000; 25:756–9
117. Twomey LT, Taylor JR, Taylor MM: Unsuspected damage to lumbar zygapophyseal (facet) joints after motor-vehicle accidents. Med J Aust 1989; 151:215–7
118. Long DM, BenDebba M, Torgerson TS, Boyd RJ, Dawson EG, Hardy RW, Robertson JT, Sypert GW, Watts C: Persistent back pain and sciatica in the United States: Patient characteristics. J Spinal Disord 1996; 9:40–58
119. Murtagh FR: Computed tomography and fluoroscopy guided anesthesia and steroid injection in facet syndrome. Spine 1988; 13:686–9
120. Destouet JM, Gilula LA, Murphy WA, Monsees B: Lumbar facet joint injection: Indication, technique, clinical correlation and preliminary results. Radiology 1982; 145:321–5
121. Lau LS, Littlejohn GO, Miller MH: Clinical evaluation of intra-articular injections for lumbar facet joint pain. Med J Aust 1985; 143:563–5
122. Moran R, O'Connell D, Walsh MG: The diagnostic value of facet joint injections. Spine 1988; 13:1407–10
123. Raymond J, Dumas JM: Intra-articular facet block: Diagnostic test or therapeutic procedure? Radiology 1984; 151:333–6
124. Lewinnek GE, Warfield CA: Clin Orthop Relat Res 1986; 213:216–22
125. Carrera GF: Lumbar facet joint injection in low back pain and sciatica: Preliminary results. Radiology 1980; 137:665–7
126. Sowa G: Facet-mediated pain. Dis Mon 2005; 51:18–33
127. Dreyer SJ, Dreyfuss PH: Low back pain and the zygapophysial (facet) joints. Arch Phys Med Rehabil 1996; 17:290–300
128. Dreyfuss PH, Dreyer SJ: Lumbar zygapophysial joint (facet) injections. Spine J 2003; 3:50S–9S
129. Manchikanti L, Pampati V, Fellows B, Bakhit CE: The diagnostic validity and therapeutic value of lumbar facet joint nerve blocks with or without adjuvant agents. Curr Rev Pain 2000; 4:337–44
130. Schwarzer AC, Aprill CN, Derby R, Fortin J, Kine G, Bogduk N: The false-positive rate of uncontrolled diagnostic blocks of the lumbar zygapophysial joints. Pain 1994; 58:195–200
131. Manchikanti L, Pampati V, Fellows B, Bakhit CE: Prevalence of lumbar facet joint pain in chronic low back pain. Pain Physician 1999; 2:59–64
132. Schwarzer AC, Wang SC, Bogduk N, McNaught PJ, Laurent R: Prevalence and clinical features of lumbar zygapophysial joint pain: A study in an Australian population with chronic low back pain. Ann Rheum Dis 1995; 54:100–6

Downloaded from http://pubs.asahq.org/anesthesiology/article-pdf/106/3/591/363690/0000542-200703000-00024.pdf by guest on 23 September 2024

Copyright © by the American Society of Anesthesiologists. Unauthorized reproduction of this article is prohibited.

133. Bogduk N: International Spinal Injection Society guidelines for the performance of spinal injection procedures. Part I: Zygapophysial joint blocks. Clin J Pain 1997; 13:285–302
134. Newton W, Curtis P, Witt P, Hobler K: Prevalence of subtypes of low back pain in a defined population. J Fam Pract 1997; 45:331–5
135. Cohen SP, Larkin T, Chang A, Stojanovic M: The causes of false-positive medial branch blocks in soldiers and retirees. Mil Med 2004; 169:781–6
136. Johnston HM: The cutaneous branches of the posterior primary divisions of the spinal nerves, and their distribution in the skin. J Anat Physiol 1908; 43:80–91
137. Cohen SP: Sacroiliac joint pain: A comprehensive review of anatomy, diagnosis and treatment. Anesth Analg 2005; 101:1440–53
138. Bough B, Thakore J, Davies M, Dowling F: Degeneration of the lumbar facet joints: Arthrography and pathology. J Bone Joint Surg (Br) 1990; 72:275–6
139. Schwarzer AC, Derby R, Aprill CN, Fortin J, Kine G, Bogduk N: The value of the provocation response in lumbar zygapophyseal joint injections. Clin J Pain 1994; 10:309–13
140. Schwarzer AC, Aprill CN, Bogduk N: The sacroiliac joint in chronic low back pain. Spine 1995; 20:31–7
141. Slipman CW, Plastaras CT, Palmitier RA, Huston CW, Sterenfeld EB: Symptom provocation of fluoroscopically guided cervical nerve root stimulation: Are dynatomal maps identical to dermatomal maps? Spine 1998; 23:2235–42
142. Fairbank JC, Park WM, McCall IW, O'Brien JP: Apophyseal injection of local anesthetic as a diagnostic aid in primary low-back pain syndromes. Spine 1981; 6:598–605
143. Helbig T, Lee CK: The lumbar facet syndrome. Spine 1988; 13:61–4
144. Carrera GF, Williams AL: Current concepts in evaluation of the lumbar facet joints. Crit Rev Diagn Imaging 1984; 21:85–104
145. Weishaupt D, Zanetti M, Boos N, Hodler J: MR imaging and CT in osteoarthritis of the lumbar facet joints. Skeletal Radiol 1999; 28:215–9
146. Leone A, Aulisa L, Tamburrelli F, Lupparelli S, Tartaglione T: The role of computed tomography and magnetic resonance in assessing degenerative arthropathy of the lumbar articular facets [in Italian]. Radiol Med 1994; 88:547–52
147. Weishaupt D, Zanetti M, Hodler J, Boos N: MR imaging of the lumbar spine: Prevalence of intervertebral disk extrusion and sequestration, nerve root compression, end plate abnormalities, and osteoarthritis of the facet joints in asymptomatic volunteers. Radiology 1998; 209:661–6
148. Wiesel SW, Tsourmas N, Feffer HL, Citrin CM, Patronas N: A study of computer-assisted tomography: I. The incidence of positive CAT scans in an asymptomatic group of patients. Spine 1984; 9:549–5
149. Jensen MC, Brant-Zawadzki MN, Obuchowski N, Modic MT, Malkasian D, Ross JS: Magnetic resonance imaging of the lumbar spine in people without back pain. N Engl J Med 1994; 331:69–73
150. Dolan AL, Ryan PJ, Arden NK, Stratton R, Wedley JR, Hamann W, Fogelman I, Gibson T: The value of SPECT scans in identifying back pain likely to benefit from facet joint injection. Br J Rheum 1996; 35:1269–73
151. Raymond J, Dumas JM, Lisbona R: Nuclear imaging as a screening test for patients referred for intraarticular facet block. J Can Assoc Radiol 1984; 35:291–2
152. Schwarzer AC, Wang SC, O'Driscoll D, Harrington T, Bogduk N, Laurent R: The ability of computed tomography to identify a painful zygapophysial joint in patients with chronic low back pain. Spine 1995; 20:907–12
153. Cohen SP, Hurley RW, Christo PJ, Winkley J, Mohiuddin MM, Stojanovic MP: Clinical predictors of success and failure for lumbar facet radiofrequency denervation. Clin J Pain 2007; 23:45–52
154. Kawaguchi Y, Matsuno H, Kanamori M, Ishihara H, Ohmori K, Kimura T: Radiologic findings of the lumbar spine in patients with rheumatoid arthritis, and a review of pathologic mechanisms. J Spinal Disord Tech 2003; 16:38–43
155. Kellegren JH: On the distribution of pain arising from deep somatic structures with charts of segmental pain areas. Clin Sci 1939; 4:35–46
156. Nash TP: Facet joints: Intra-articular steroids or nerve block? Pain Clin 1990; 3:77–82
157. van Kleef M, Barendse GA, Kessels A, Voets HM, Weber WE, de Lange S: Randomized trial of radiofrequency lumbar facet denervation for chronic low back pain. Spine 1999; 24:1937–42
158. Gallagher J, Petriccione di Vadi PL, Wedley JR, Hamann W, Ryan P, Chikanza I, Kirkham B, Price R, Watson MS, Grahame R, Wood S: Radiofrequency facet joint denervation in the treatment of low back pain: A prospective controlled double-blind study to assess its efficacy. Pain Clinic 1994; 7:193–8
159. Leclaire R, Fortin L, Lambert R, Bergeron YM, Rossignol M: Radiofrequency facet joint denervation in the treatment of low back pain: A placebo-controlled clinical trial to assess efficacy. Spine 2001; 26:1411–7
160. van Wijk RM, Geurts JW, Wynne HJ, Hammink E, Buskens E, Lousberg R, Knape JT, Groen GJ: Radiofrequency denervation of lumbar facet joints in the treatment of chronic low back pain: A randomized, double-blind, sham lesion-controlled trial. Clin J Pain 2005; 21:335–44
161. Greher M, Scharbert G, Kamolz LP, Beck H, Gustorff B, Kirchmair L, Kapral S: Ultrasound-guided lumbar facet nerve block: A sonoanatomic study of a new methodological approach. Anesthesiology 2004; 100:1242–8
162. Greher M, Kirchmair L, Enna B, Kovacs P, Gustorff B, Kapral S, Moriggl B: Ultrasound-guided lumbar facet nerve block: Accuracy of a new technique confirmed by computed tomography. Anesthesiology 2004; 101:1195–2000
163. Galiano K, Obwegeser AA, Bodner G, Freund M, Maurer H, Kamelger FS, Schatzer R, Ploner F: Ultrasound guidance for facet joint injections in the lumbar spine: A computed tomography-controlled feasibility study. Anesth Analg 2005; 101:579–83
164. Kullmer K, Rompe JD, Lowe A, Herbsthofer B, Eysel P: Ultrasound image of the lumbar spine and the lumbosacral transition: Ultrasound anatomy and possibilities for ultrasonically-controlled facet joint infiltration [in German]. Z Orthop Ihre Grenzgeb 1997; 135:310–4
165. Lord SM, Barnsley L, Bogduk N: The utility of comparative local anesthetic blocks *versus* placebo-controlled blocks for the diagnosis of cervical zygapophysial joint pain. Clin J Pain 1995; 11:208–13
166. Hogan QH, Abram SE: Neural blockade for diagnosis and prognosis: A review. Anesthesiology 1997; 86:216–41
167. Manchikanti L, Pampati V, Damron K: The role of placebo and nocebo effects of perioperative administration of sedatives and opioids in interventional pain management. Pain Physician 2005; 8:349–55
168. Manchikanti L, Pampati V, Damron KS, McManus CD, Jackson SD, Barnhill RC, Martin JC: The effect of sedation on diagnostic validity of facet joint nerve blocks: An evaluation to assess similarities in population with involvement in cervical and lumbar regions. Pain Physician 2006; 1:47–52
169. Cohen SP, Mullings R, Abdi S: The pharmacologic treatment of muscle pain. Anesthesiology 2004; 101:495–526
170. Cucuzzella TR, Delport EG, Kim N, Marley J, Pruitt C, Delport AG: A survey: Conscious sedation with epidural and zygapophyseal injections: Is it necessary? Spine J 2006; 6:364–9
171. North RB, Kidd DH, Zahurak M, Piantadosi S: Specificity of diagnostic nerve blocks: A prospective, randomized study of sciatica due to lumbosacral spine disease. Pain 1996; 65:77–85
172. Ambroz C, Scott A, Ambroz A, Talbott EO: Chronic low back pain assessment using surface electromyography. J Occup Environ Med 2000; 42:660–9
173. Geisser ME, Ranavava M, Haig AJ, Roth RS, Zucker R, Ambroz C, Caruso M: A meta-analytic review of surface electromyography among persons with low back pain and normal, healthy controls. J Pain 2005; 6:711–26
174. Browning R, Jackson JL, O'Malley PG: Cyclobenzaprine and back pain: A meta-analysis. Arch Intern Med 2001; 161:1613–20
175. Foster L, Clapp L, Erickson M, Jabbari B: Botulinum toxin A and chronic low back pain: A randomized, double-blind study. Neurology 2001; 56:1290–3
176. Ackerman WE, Munir MA, Zhang JM, Ghaleb A: Are diagnostic lumbar facet injections influenced by pain of muscular origin? Pain Practice 2004; 4:286–91
177. Woolf CJ, McMahon SB: Injury-induced plasticity of the flexor reflex in chronic decerebrate rats. Neuroscience 1985; 16:395–404
178. Woolf CJ, Wiesenfeld-Hallin Z: The systemic administration of local anaesthetics produces a selective depression of C-afferent fibre evoked activity in the spinal cord. Pain 1985; 23:361–74
179. Stojanovic MP, Zhou Y, Hord ED, Vallejo R, Cohen SP: Single needle approach for multiple medial branch blocks: A new technique. Clin J Pain 2003; 19:134–7
180. Stojanovic MP, Dey D, Hord ED, Zhou Y, Cohen SP: A prospective crossover comparison study of the single-needle and multiple-needle techniques for facet-joint medial branch block. Reg Anesth Pain Med 2005; 30:484–90
181. Berven S, Tay BB, Colman W, Hu SS: The lumbar zygapophyseal (facet) joints: A role in the pathogenesis of spinal pain syndromes and degenerative spondylolisthesis. Semin Neurol 2002; 22:187–95
182. Dreyfuss P, Halbrook B, Pauza K, Joshi A, McLarty J, Bogduk N: Efficacy and validity of radiofrequency neurotomy for chronic lumbar zygapophysial joint pain. Spine 2000; 25:1270–7
183. Kornick C, Kramarich SS, Lamer TJ, Sitzman BT: Complications of lumbar facet radiofrequency denervation. Spine 2004; 29:1352–4
184. Dobrogowski J, Wrzosek A, Wordliczek J: Radiofrequency denervation with or without addition of pentoxifylline or methylprednisolone for chronic lumbar zygapophysial joint pain. Pharmacol Rep 2005; 57:475–80
185. Bogduk N, Holmes S: Controlled zygapophysial joint blocks: The travesty of cost-effectiveness. Pain Med 2000; 1:24–34
186. Geisser ME, Wiggert EA, Haig AJ, Colwell MO: A randomized, controlled trial of manual therapy and specific adjuvant exercise for chronic low back pain. Clin J Pain 2005; 21:463–70
187. Sherman KJ, Cherkin DC, Erro J, Miglioretti DL, Deyo R: Comparing yoga, exercise, and a self-care book for chronic low back pain: A randomized, controlled trial. Ann Intern Med 2005; 143:849–56
188. Maul I, Laubli T, Oliveri M, Krueger H: Long-term effects of supervised physical training in secondary prevention of low back pain. Eur Spine J 2005; 14:599–611
189. Staal JB, Hlobil H, Twisk JW, Smid T, Koke AJ, van Mechelen W: Graded activity for low back pain in occupational health care: A randomized, controlled trial. Ann Intern Med 2004; 140:77–84
190. Williams KA, Petronis J, Smith D, Goodrich D, Wu J, Ravi N, Doyle EJ Jr, Gregory Juckett R, Munoz Kolar M, Gross R, Steinberg L: Effect of Iyengar yoga therapy for chronic low back pain. Pain 2005; 115:107–17
191. Andersson GB, Lucente T, Davis AM, Kappler RE, Lipton JA, Leurgans S: A comparison of osteopathic spinal manipulation with standard care for patients with low back pain. N Engl J Med 1999; 341:1426–31
192. Giles LG, Muller R: Chronic spinal pain: A randomized clinical trial

Downloaded from http://pubs.asahq.org/anesthesiology/article-pdf/106/3/591/363690/0000542-200703000-00024.pdf by guest on 23 September 2024

Copyright © by the American Society of Anesthesiologists. Unauthorized reproduction of this article is prohibited.

comparing medication, acupuncture, and spinal manipulation. Spine 2003; 28: 1490–502

193. Licciardone JC, Stoll ST, Fulda KG, Russo DP, Siu J, Winn W, Swift J Jr: Osteopathic manipulative treatment for chronic low back pain: A randomized controlled trial. Spine 2003; 28:1355–62

194. Meng CF, Wang D, Ngeow J, Lao L, Peterson M, Paget S: Acupuncture for chronic low back pain in older patients: A randomized, controlled trial. Rheumatology 2003; 42:1508–17

195. Tsukayama H, Yamashita H, Amagai H, Tanno Y: Randomised controlled trial comparing the effectiveness of electroacupuncture and TENS for low back pain: A preliminary study for a pragmatic trial. Acupunct Med 2002; 20:175–80

196. Kerr DP, Walsh DM, Baxter D: Acupuncture in the management of chronic low back pain: A blinded randomized controlled trial. Clin J Pain 2003; 19:364–70

197. Brinkhaus B, Witt CM, Jena S, Linde K, Streng A, Wagenpfeil S, Irnich D, Walther HU, Melchart D, Willich SN: Acupuncture in patients with chronic low back pain: A randomized controlled trial. Arch Intern Med 2006; 166:450–7

198. Zerbini C, Ozturk ZE, Grifka J, Maini M, Nilganuwong S, Morales R, Hupli M, Shivaprakash M, Giezek H: Efficacy of etoricoxib 60 mg/day and diclofenac 150 mg/day in reduction of pain and disability in patients with chronic low back pain: Results of a 4-week, multinational, randomized, double-blind study. Curr Med Res Opin 2005; 21:2037–49

199. Videman T, Osterman K: Double-blind parallel study of piroxicam *versus* indomethacin in the treatment of low back pain. Ann Clin Res 1984; 16:156–60

200. Mens JM: The use of medication in low back pain. Best Pract Res Clin Rheumatol 2005; 19:609–21

201. Schnitzer TJ, Ferraro A, Hunsche E, Kong SX: A comprehensive review of clinical trials on the efficacy and safety of drugs for the treatment of low back pain. J Pain Symptom Manage 2004; 28:72–95

202. Polatin PB, Kinney RK, Gatchel RJ, Lillo E, Mayer TG: Psychiatric illness and chronic low-back pain: The mind and the spine-which goes first? Spine 1993; 18:66–71

203. Fayad F, Lefevre-Colau MM, Poiraudeau S, Fermanian J, Rannou F, Wlodyka Demaille S, Benyahya R, Revel M: Chronicity, recurrence, and return to work in low back pain: Common prognostic factors [in French]. Ann Readapt Med Phys 2004; 47:179–89

204. Lilius G, Laasonen EM, Myllynen P, Harilainen A, Salo L: Lumbar facet joint syndrome: Significance of non-organic signs. A randomized placebo-controlled clinical study [in French]. Rev Chir Orthop Reparatrice Appar Mot 1989; 75:493–500

205. Lippitt AB: The facet joint and its role in spine pain: Management with facet joint injections. Spine 1984; 9:746–50

206. Carette S, Marcoux S, Truchon R, Grondin C, Gagnon J, Allard Y, Latulippe M: A controlled trial of corticosteroid injections into facet joints for chronic low back pain. N Engl J Med 1991; 325:1002–7

207. Lilius G, Laasonen EM, Harilainen A, Gronlund G: Lumbar facet joint syndrome: A randomised clinical trial. J Bone Joint Surg (Br) 1989; 71:681–4

208. Fuchs S, Erbe T, Fischer HL, Tibesku CO: Intraarticular hyaluronic acid *versus* glucocorticoid injections for nonradicular pain in the lumbar spine. J Vasc Interv Radiol 2005; 16:1493–8

209. Blanchard J, Ramamurthy S, Walsh N, Hoffman J, Schoenfeld L: Intravenous regional sympatholysis: A double-blind comparison of guanethidine, reserpine, and normal saline. J Pain Symptom Manage 1990; 5:357–61

210. Frost FA, Jessen R, Siggaard-Anderson J: A control, double-blind comparison of mepivacaine injection *versus* saline injection for myofascial pain. Lancet 1980; 1:499–500

211. Price DD, Long S, Wilsey B, Rafii A: Analysis of peak magnitude and duration of analgesia produced by local anesthetics injected into sympathetic ganglia of complex regional pain syndrome patients. Clin J Pain 1998; 14:216–26

212. Resnick DK, Choudhri TF, Dailey AT, Groff MW, Khoo L, Matz PG, Mummaneni P, Watters WC III, Wang J, Walters BC, Hadley MN: American Association of Neurological Surgeons/Congress of Neurological Surgeons. Guidelines for the performance of fusion procedures for degenerative disease of the lumbar spine. Part 13: Injection therapies, low-back pain, and lumbar fusion. J Neurosurg Spine 2005; 2:707–15

213. Bogduk N: A narrative review of intra-articular corticosteroid injections for low back pain. Pain Med 2005; 6:287–96

214. Slipman CW, Bhat AL, Gilchrist RV, Isaac Z, Chou L, Lenrow DA: A critical review of the evidence for the use of zygapophysial injections and radiofrequency denervation in the treatment of low back pain. Spine J 2003; 3:310–6

215. Pneumaticos SG, Chatziioannou SN, Hipp JA, Moore WH, Esses SI: Low back pain: Prediction of short-term outcome of facet joint injection with bone scintigraphy. Radiology 2006; 238:693–8

216. Holder LE, Machin JL, Asdourian PL, Links JM, Sexton CC: Planar and high-resolution SPECT bone imaging in the diagnosis of facet syndrome. J Nucl Med 1995; 36:37–44

217. Lord SM, Barnsley L, Wallis BJ, McDonald GJ, Bogduk N: Percutaneous radio-frequency neurotomy for chronic cervical zygapophyseal-joint pain. N Engl J Med 1996; 335:1721–6

218. Cohen SP, Abdi S: Lateral branch blocks as a treatment for sacroiliac joint pain: A pilot study. Reg Anesth Pain Med 2003; 28:113–9

219. Yin W, Willard F, Carreiro J, Dreyfuss P: Sensory stimulation-guided sacroiliac joint radiofrequency neurotomy: Technique based on neuroanatomy of the dorsal sacral plexus. Spine 2003; 28:2419–25

220. Barendse GA, van Den Berg SG, Kessels AH, Weber WE, van Kleef M: Randomized controlled trial of percutaneous intradiscal radiofrequency thermocoagulation for chronic discogenic back pain: Lack of effect from a 90-second 70 C lesion. Spine 2001; 26:287–92

221. Pevzner E, David R, Leitner Y, Pekarsky I, Folman Y, Gepstein R: Pulsed radiofrequency treatment of severe radicular pain [in Hebrew]. Harefuah 2005; 144:178–80

222. Niemisto L, Kalso E, Malmivaara A, Seitsalo S, Hurri H: Radiofrequency denervation for neck and back pain: A systematic review of randomized controlled trials. Cochrane Database Syst Rev 2003; 1:CD004058

223. Burton CV: Percutaneous radiofrequency facet denervation. Appl Neurophysiol 1977; 39:80–86

224. Houston JR: A study of subcutaneous rhizolysis in the treatment of chronic backache. J R Coll Gen Pract 1975; 25:696–7

225. McCulloch JA: Percutaneous radiofrequency lumbar rhizolysis (rhizotomy). Appl Neurophysiol 1976– 1977; 39:87–96

226. Ogsbury JS, Simon RH, Lehman RA: Facet denervation in the treatment of low back syndrome. Pain 1977; 3:257–63

227. Oudenhoven RC: The role of laminectomy, facet rhizotomy and epidural steroids. Spine 1979; 4:145–7

228. Rashbaum RF: Radiofrequency facet denervation. Orthop Clin North Am 1983; 14:569–75

229. Lora J, Long D: So-called facet denervation in the management of intractable back pain. Spine 1976; 1:121–6

230. McCulloch JA, Organ LW: Percutaneous radiofrequency lumbar rhizolysis (rhizotomy). Can Med Assoc J 1977; 116:30–2

231. Schaerer JP: Radiofrequency facet rhizotomy in the treatment of chronic neck and low back pain. Int Surg 1978; 63:53–9

232. North RB, Han M, Zahurak M, Kidd DH: Radiofrequency lumbar facet denervation: Analysis of prognostic factors. Pain 1994; 57:77–83

233. Geurts JW, Van Wijk RM, Stolker RJ, Groen GJ: Efficacy of radiofrequency procedures for the treatment of spinal pain: A systematic review of randomized clinical trials. Reg Anesth Pain Med 2001; 26:394–400

234. Lau P, Mercer S, Govind J, Bogduk N: The surgical anatomy of lumbar medial branch neurotomy (facet denervation). Pain Med 2004; 5:289–98

235. Bogduk N, Macintosh J, Marsland A: Technical limitations to the efficacy of radiofrequency neurotomy for spinal pain. Neurosurgery 1987; 20:529–34

236. Chua WH, Bogduk N: The surgical anatomy of thoracic facet denervation. Acta Neurochir 1995; 136:140–4

237. Vinas FC, Zamorano L, Dujovny M, Zhao JZ, Hodgkinson D, Ho KL, Ausman JI: *In vivo* and *in vitro* study of the lesions produced with a computerized radiofrequency system. Stereotact Funct Neurosurg 1992; 58:121–33

238. Buijs EJ, van Wijk RM, Geurts JW, Weeseman RR, Stolker RJ, Groen GG: Radiofrequency lumbar facet denervation: A comparative study of the reproducibility of lesion size after 2 current radiofrequency techniques. Reg Anesth Pain Med 2004; 29:400–7

239. Demazumder D, Mirotznik MS, Schwartzman D: Comparison of irrigated electrode designs for radiofrequency ablation of myocardium. J Interv Card Electrophysiol 2001; 5:391–400

240. Benzon HT: Epidural steroid injections for low back pain and lumbosacral radiculopathy. Pain 1986; 24:277–95

241. Quigley MR, Bost J, Maroon JC, Elrifai A, Panahandeh M: Outcome after microdiscectomy: Results of a prospective single institutional study. Surg Neurol 1998; 49:263–7

242. North RB, Campbell JN, James CS, Conover-Walker MK, Wang H, Piantadosi S, Rybock JD, Long DM: Failed back surgery syndrome: 5-year follow-up in 102 patients undergoing repeated operation. Neurosurgery 1991; 28:685–90

243. Schofferman J, Kine G: Effectiveness of repeated radiofrequency neurotomy for lumbar facet pain. Spine 2004; 29:2471–3

244. Mikeladze G, Espinal R, Finnegan R, Routon J, Martin D: Pulsed radiofrequency application in treatment of chronic zygapophyseal joint pain. Spine J 2003; 360–2

245. Barlocher CB, Krauss JK, Seiler RW: Kryorhizotomy: An alternative technique for lumbar medial branch rhizotomy in lumbar facet syndrome. J Neurosurg 2003; 98 (suppl):14–20

246. Schuster GD: The use of cryoanalgesia in the painful facet syndrome. J Neurol Orthopaed Surg 1982; 3:271–4

247. Staender M, Maerz U, Tonn JC, Steude U: Computerized tomography-guided kryorhizotomy in 76 patients with lumbar facet syndrome. J Neurosurg Spine 2005; 3:444–9

248. Brechner T: Percutaneous cryogenic neurolysis of the articular nerve of Luschka. Reg Anesth 1981; 6:18–22

249. Selby DK, Paris SV: Anatomy of facet joints and its correlation with low back pain. Contemp Orthop 1981; 312:1097–103

250. Silvers HR: Lumbar percutaneous facet rhizotomy. Spine 1990; 15:36–40

251. Kay J, Findling JW, Raff H: Epidural triamcinolone suppresses the pituitary-adrenal axis in human subjects. Anesth Analg 1994; 79:501–5

252. Ward A, Watson J, Wood P, Dunne C, Kerr D: Glucocorticoid epidural for sciatica: Metabolic and endocrine sequelae. Rheumatology 2002; 41:68–71

253. Alcock E, Regaard A, Browne J: Facet joint injection: A rare form of epidural abscess formation. Pain 2003; 103:209–10

Downloaded from http://pubs.asahq.org/anesthesiology/article-pdf/106/3/591/363690/0000542-200703000-00024.pdf by guest on 23 September 2024

Copyright © by the American Society of Anesthesiologists. Unauthorized reproduction of this article is prohibited.

254. Orpen NM, Birch NC: Delayed presentation of septic arthritis of a lumbar facet joint after diagnostic facet joint injection. J Spinal Disord Tech 2003; 16:285–7
255. Gaul C, Neundorfer B, Winterholler M: Iatrogenic (para-) spinal abscesses and meningitis following injection therapy for low back pain. Pain 2005; 116:407–10
256. Goldstone JC, Pennant JH: Spinal anaesthesia following facet joint injection: A report of two cases. Anaesthesia 1987; 42:754–6
257. Cohen SP: Postdural puncture headache and treatment following successful lumbar facet block. Pain Digest 1994; 4:283–4
258. Tzaan WC, Tasker RR: Percutaneous radiofrequency facet rhizotomy: Experience with 118 procedures and reappraisal of its value. Can J Neurol Sci 2000; 27:125–30
259. Katz SS, Savitz MH: Percutaneous radiofrequency rhizotomy of the lumbar facets. Mount Sinai J Med 1986; 53:523–5
260. Deyo RA, Nachemson A, Mirza SK: Spinal-fusion surgery: The case for restraint. N Engl J Med 2004; 350:722–6
261. Gibson JN, Waddell G, Grant IC: Surgery for degenerative lumbar spondylosis. Cochrane Database Syst Rev 2000; 3:CD001352
262. Jackson RP: The facet syndrome: Myth or reality? Clin Orthop Relat Res 1992; 279:110–21
263. Esses SI, Botsford DJ, Kostuik JP: The role of external spinal skeletal fixation in the assessment of low-back disorders. Spine 1989; 14:594–601
264. Esses SI, Moro JK: The value of facet joint blocks in patient selection for lumbar fusion. Spine 1993; 18:185–90
265. Lovely TJ, Rastogi P: The value of provocative facet blocking as a predictor of success in lumbar spine fusion. J Spinal Disord 1997; 10:512–7
266. Manchikanti L, Pampati V, Fellows B, Baha AG: The inability of the clinical picture to characterize pain from facet joints. Pain Physician 2000; 3:158–66
267. Manchikanti L, Boswell MV, Singh V, Pampati V, Damron KS, Beyer CD: Prevalence of facet joint pain in chronic spinal pain of cervical, thoracic, and lumbar regions. BMC Musculoskelet Disord 2004; 5:15
268. Lynch MC, Taylor JF: Facet joint injection for low back pain: A clinical study. J Bone Joint Surg (Br) 1986; 1:138–41
269. Marks R: Distribution of pain provoked from lumbar facet joints and related structures during diagnostic spinal infiltration. Pain 1989; 39:37–40
270. Fukui S, Ohseto K, Shiotani M, Ohno K, Karasawa H, Naganuma Y: Distribution of referred pain from the lumbar zygapophyseal joints and dorsal rami. Clin J Pain 1997; 13:303–7
271. Young S, Aprill C, Laslett M: Correlation of clinical examination characteristics with three sources of chronic low back pain. Spine J 2003; 3:460–5
272. Lilius G, Harilainen A, Laasonen EM, Myllynen P: Chronic unilateral low-back pain: Predictors of outcome of facet joint injections. Spine 1990; 15:780–2
273. Laslett M, Oberg B, Aprill CN, McDonald B: Zygapophysial joint blocks in chronic low back pain: A test of Revel's model as a screening test. BMC Musculoskelet Disord 2004; 5:43
274. Laslett M, McDonald B, Aprill CN, Tropp H, Oberg B: Clinical predictors of screening lumbar zygapophyseal joint blocks: Development of clinical prediction rules. Spine J 2006; 6:370–9
275. Jadad AR, Moore RA, Carroll D, Jenkinson C, Reynolds DJ, Gavaghan DJ, McQuay HJ: Assessing the quality of randomised clinical trials: Is blinding necessary? Control Clin Trials 1996; 17:1–12
276. Sanders M, Zuurmond WW: Percutaneous intra-articular lumbar facet joint denervation in the treatment of low back pain: A comparison with percutaneous extra-articular lumbar facet denervation. Pain Clinic 1999; 11: 329–35
277. Taylor JR, Twomey LT: Age changes in lumbar zygapophyseal joints: Observations on structure and function. Spine 1986; 11:739–45

Downloaded from http://pubs.asahq.org/anesthesiology/article-pdf/106/3/591/363690/0000542-200703000-00024.pdf by guest on 23 September 2024

Copyright © by the American Society of Anesthesiologists. Unauthorized reproduction of this article is prohibited.